


Society for Endocrinology



CLINICAL GUIDELINES

UK Guidelines for the Management of Pituitary Apoplexy



Society for
Endocrinology



Royal College
of Physicians



Executive Summary

Classical pituitary apoplexy is a medical emergency and rapid replacement with hydrocortisone maybe life saving. It is a clinical syndrome characterised by the sudden onset of headache, vomiting, visual impairment and decreased consciousness caused by haemorrhage and/or infarction of the pituitary gland. It is associated with the sudden onset of headache accompanied or not by neurological symptoms involving the second, third, fourth and sixth cranial nerves. If diagnosed patients should be referred to a multidisciplinary team comprising, amongst others, of a neurosurgeon and an endocrinologist. Apart from patients with worsening neurological symptoms in whom surgery is indicated it is unclear currently for the majority of patients whether conservative or surgical management carries the best outcome. There needs to be careful monitoring for recurrence of tumour growth.

Summary of recommendations

3.1 Clinical assessment

- A diagnosis of pituitary apoplexy should be considered in all patients presenting with acute severe headache with or without neuro-ophthalmic signs; (✓)
- Patients who have been diagnosed with pituitary tumour should be given clear information regarding the signs and symptoms of pituitary apoplexy and the precipitating factors; (✓)
- Patients known to have a pituitary tumour must be observed for signs and symptoms of pituitary apoplexy when performing pituitary stimulation tests, commencing anticoagulation therapy or undertaking coronary artery bypass or other major surgery; (IV, C)
- Initial assessment of the patients presenting with symptoms consistent with pituitary apoplexy should include a detailed history focusing on symptoms of pituitary dysfunction e.g. symptoms of hypogonadism, followed by a thorough physical examination including cranial nerves and visual fields to confrontation; (✓)
- Formal visual fields assessment, using Humphrey visual field analyzer or Goldmann perimeter must be undertaken when the patient is clinically stable, preferably within 24 hours of suspected diagnosis; (✓)
- In haemodynamically unstable patients, in whom standard supportive measures are required to ensure haemodynamic stability, intravenous hydrocortisone should be administered after drawing blood samples for baseline endocrine function tests including random serum cortisol, FT4 and TSH. (IV, C)

3.2 Endocrine assessment

- All patients with suspected pituitary apoplexy should have urgent blood samples drawn to check electrolytes, renal function, liver function, clotting screen, full blood count, and random cortisol, PRL, FT4, TSH, IGF1, GH, LH, FSH and testosterone in men, oestradiol in women. (IV, C)

3.3 Radiological assessment

- Urgent MRI scan must be done in all patients with suspected pituitary apoplexy to confirm the diagnosis; (III, B)
- A dedicated pituitary CT scan is indicated if the MRI scan is either contraindicated or not possible; (IV, C)
- The results of the MRI or CT scan should be clearly explained to the patient as soon as possible after the investigation. (✓)

4. Management

4.1 Steroid therapy in pituitary apoplexy

- The immediate medical management of patients with pituitary apoplexy should include careful assessment of fluid and electrolyte balance, replacement of corticosteroids and supportive measures to ensure haemodynamic stability; (III, B)
- Patients with pituitary apoplexy, who are haemodynamically unstable should be commenced on empirical steroid therapy. In adults hydrocortisone 100-200mg as an intravenous bolus is appropriate, followed either by 2-4mg per hour by continuous intravenous infusion or 50-100mg six hourly by intramuscular injection, after drawing blood samples for random cortisol, FT4, TSH, PRL, IGF1, GH, LH, FSH, testosterone in men, oestradiol in women, electrolytes, renal function, liver function, full blood count and clotting screen; (IV, C)
- Indications for empirical steroid therapy in patients with pituitary apoplexy are haemodynamic instability, altered consciousness level, reduced visual acuity and severe visual field defects; (IV, C)
- Patients who do not fulfil the criteria for urgent empirical steroid therapy should be considered for treatment with steroids, if their 09.00 serum cortisol is less than 550nmol/l; (IV, C)

- Further neuro-ophthalmic assessments, to check the visual acuity, visual fields and ocular paresis must be undertaken, when the patient is clinically stable. (✓)

4.2 Where should patients with pituitary apoplexy be managed?

- Once the diagnosis has been confirmed, it is recommended that all patients be transferred once medically stabilised following liaison and advice from the specialist neurosurgical/endocrine team to the local neurosurgical/endocrine team as soon as possible. Neurosurgical HDU facilities must be available. This team must have access to specialist endocrine and ophthalmological expertise. (✓)

4.3 Surgery or conservative management?

- Patients with pituitary apoplexy should first be stabilized medically with steroid replacement if needed; (✓)
- The decision to manage conservatively or with surgical intervention should be made carefully by a multidisciplinary team, including experts in neurosurgery, endocrinology and ophthalmology; (✓)
- The rationale behind the clinical decisions should be fully explained to the patient and when possible their informed consent should be obtained; (✓)
- Leaflets explaining the diagnosis of pituitary tumours and pituitary apoplexy should be provided to the patient. (✓)

4.4 Indications for conservative management

- Patients with pituitary apoplexy, who are without any neuro-ophthalmic signs or mild and stable signs can be considered for conservative management with careful monitoring; (III, B)
- In patients with reduced visual acuity or defective visual fields, formal assessment of visual fields and acuity should be performed every day until clear trend of improvement is observed; (✓)
- Acutely unwell patients should have neurological assessment every hour and any deterioration in neurological status should prompt urgent senior medical review with consideration to proceed with surgery; (✓)
- The frequency of neurological assessment could be gradually reduced to every four to six hours, when the patients are stable; (✓)
- Renal function and electrolytes should be checked daily. Further endocrine specialist evaluation to assess possible under or over secretion of pituitary hormones should be undertaken in stable patients. (✓)

4.5 Indications for surgical management

- Patients with severe neuro-ophthalmic signs such as severely reduced visual acuity, severe and persistent or deteriorating visual field defects or deteriorating level of consciousness should be considered for surgical management; (III, B)
- Ocular paresis due to involvement of III, IV or VI cranial nerves in cavernous sinus in the absence of visual field defects or reduced visual acuity is not in itself an indication for immediate surgery. Resolution will typically occur within days or weeks with conservative management; (III, B)
- We would recommend the surgery to be performed by an experienced pituitary surgeon rather than by the on call neurosurgical team unless if the clinical situation warrants immediate intervention; (IV, C)
- Surgery should be performed preferably within the first seven days of onset of symptoms. (III, B)

4.6 The indications for surgery in those initially managed conservatively

- The presence of a new or deteriorating visual deficit or neurological deterioration should prompt further urgent imaging with a view to decompressive surgery (including external ventricular drain (EVD) placement in the presence of hydrocephalus). (IV, C)

5. Post-operative care

5.1 Immediate post-operative care

- Patients should be reviewed every hour to assess the fluid balance and serum urea, serum creatinine, serum electrolytes, plasma & urine osmolalities should be checked immediately if diabetes insipidus is suspected; (IV, C)
- Other post-operative complications such as cerebrospinal fluid leakage, visual loss, meningitis and cortisol deficiency should be proactively looked out for; (IV, C)
- Full blood count, serum urea, serum creatinine, serum electrolytes, and plasma/urine osmolalities should be checked at least once daily or more frequently if there are clinical concerns. (IV, C)

5.2 Endocrine assessment

If pre- operative steroid reserve adequate or unknown:

- Check 9am serum cortisol on day two and day three after surgery, in patients with no evidence of cortisol deficiency before operation. If already on hydrocortisone replacement, omit the evening dose for the previous day before checking. (IV, C)

If pre-operative steroid reserve deficient:

- In patients with proven cortisol deficiency before surgery, continue hydrocortisone and consider changing over to maintenance dosage when stable. These patients will need further assessment at four to eight weeks to determine whether they will need long-term steroids; (IV, C)
- FT4 and TSH should be assessed on day three or day four and thyroid hormone replacement should be considered if deficient; (IV, C)
- If FT4 and TSH normal further assessment should take place at 4 - 8 weeks. (IV, C)

5.3 Visual assessment

- Visual acuity, eye movements and visual fields should be examined at the bedside preferably within 48 hours and this should be followed by formal visual field assessment using Humphrey visual field analyzer or Goldmann perimeter; (IV, C)
- Patients who develop unexpected visual loss or significant deterioration in the visual fields should have urgent MRI scan and a review by the Neurosurgical team. (✓)

6. Long-term follow-up and outcomes

6.1 Endocrine outcomes

- All patients with pituitary apoplexy should have an endocrine review at four to eight weeks following the event. They should have full biochemical assessment of pituitary function and formal assessment of their visual acuity, eye movements and visual fields; (✓)
- Patients treated for apoplexy should have an annual biochemical assessment of pituitary function which should include FT4, TSH, LH, FSH, testosterone in men, oestradiol in women, prolactin, IGF1 and dynamic tests of cortisol and growth hormone secretion if clinically appropriate. (IV, C)

6.3 Long-term monitoring and surveillance

- Both conservatively and surgically treated patients need close radiological follow up and if residual tumour or recurrence is detected, additional modalities such as radiotherapy or redo surgery should be considered; (III, B)
- A MRI Scan is recommended at three to six months after apoplexy and thereafter an annual MRI scan should be considered for the next five years, then two yearly; (IV, C)
- All patients require at least an annual clinical review preferably in a joint endocrine/neurosurgical clinic. It is recommended that all patients must be discussed within the pituitary multidisciplinary team; (✓)
- There should be recognition of the psychological effects of pituitary disease and support from an endocrine specialist nurse and patient support organisations like the Pituitary Foundation, should be provided. (✓)

CLINICAL QUESTION

UK guidelines for the management of pituitary apoplexy

Pituitary Apoplexy Guidelines Development Group: May 2010

Senthil Rajasekarant, Mark Vanderpump‡, Stephanie Baldeweg§, Will Drake¶, Narendra Reddy†, Marian Lanyon**, Andrew Markey††, Gordon Plant**, Michael Powell‡‡, Saurabh Sinha§§ and John Wass*

†Churchill Hospital, Oxford, ‡Royal Free Hospital, London, §University College Hospital, London and Trustee and member of the Medical Committee - The Pituitary Foundation, ¶St. Bartholomew's Hospital, London and Society for Endocrinology, **University College Hospital, London, ††The Lister Hospital, London, ‡‡National Hospital for Neurology, London and Society of British Neurosurgeons, §§Royal Hallamshire Hospital, Sheffield and *Churchill Hospital, Oxford and Royal College of Physicians

Summary

Classical pituitary apoplexy is a medical emergency and rapid replacement with hydrocortisone maybe life saving. It is a clinical syndrome characterized by the sudden onset of headache, vomiting, visual impairment and decreased consciousness caused by haemorrhage and/or infarction of the pituitary gland. It is associated with the sudden onset of headache accompanied or not by neurological symptoms involving the second, third, fourth and sixth cranial nerves. If diagnosed patients should be referred to a multidisciplinary team comprising, amongst others, a neurosurgeon and an endocrinologist. Apart from patients with worsening neurological symptoms in whom surgery is indicated, it is unclear currently for the majority of patients whether conservative or surgical management carries the best outcome. Post apoplexy, there needs to be careful monitoring for recurrence of tumour growth. It is suggested that further trials be carried out into the management of pituitary apoplexy to optimize treatment.

(Received 19 July 2010; returned for revision 11 August 2010; finally revised 25 October 2010; accepted 25 October 2010)

The development and use of the guidelines

The guidelines development group

The Pituitary Apoplexy Guidelines Development Group was formed in February 2009 under the auspices of the Society for Endocrinology.

Purpose of the guidelines

It is hoped that the document will provide guidance for physicians, endocrinologists, neurosurgeons and ophthalmologists. The purpose of the guidelines is to encourage the widespread adoption of harmonized good practice in the diagnosis and management of patients with pituitary apoplexy. The guidelines are also intended to provide a basis for local and national audit and recommendations that are suitable for the audit process have been included in section 9.

The document should be considered as guidelines only; it is not intended to serve as a standard of medical care. The doctors concerned must make the management plan for an individual patient.

The process of development

The absence of consensus in the management of pituitary apoplexy has been repeatedly recognized at the annual Clinicopathological Conference on Pituitary Disease. This meeting has embraced a multidisciplinary approach to pituitary disease, with workshop discussions of cases by international representatives from endocrinology, neurosurgery, ENT, paediatrics, radiotherapy, pathology and neuroradiology since 1998. Following the 11th Clinicopathological Conference of Pituitary Disease at the Royal College of Physicians in February 2009, a subgroup of the participants agreed to take the initiative to produce a set of evidence-based guidelines that meet the requirements of all stakeholders and provide clear audit criteria for the assessment of outcomes and best practice. In February 2009, it was decided to form a guideline development group under the chairmanship of Professor John Wass which initially met in May 2009. The group members took responsibility for individual chapters and the whole group considered each draft. A patient representative was a full member of the development group.

After completion by the development group, the guidelines were subjected to external refereeing by individuals with a range of interests, including endocrinologists (Society for Endocrinology),

Correspondence: Professor John Wass, Professor of Endocrinology, Department of Endocrinology, Oxford Centre for Diabetes, Endocrinology and Metabolism, Churchill Hospital, Oxford OX3 7LJ, UK.
Tel.: 00 44 (0)1865 227621; E-mail: john.wass@noc.nhs.uk

physicians (Royal College of Physicians), neurosurgeons (including ENT and Skull Base Society), ophthalmologists, neuroradiologists (Royal College of Radiology), in district general hospitals and teaching centres as well as international experts (see Appendix 2). In addition, the draft guidelines were posted on the website of the Society for Endocrinology for three months during which comments were invited and received. Subsequent to this, the development group reviewed the comments and recommendations and appropriate revisions were made. All members of the group have approved the final draft of the guidelines.

Following an initial national audit of patient outcomes, the long-term aim is to set up a randomized controlled clinical trial of conservative versus surgical intervention in patients with pituitary apoplexy.

Mechanism for updating

The guidelines were completed in May 2010. A full review will take place after three years using data gathered during the proposed national audit.

Additional information

No declarations of interest were received from any of the professional members of the development group.

These guidelines and the accompanying patient information sets may be downloaded from:

Society for Endocrinology website: <http://www.endocrinology.org>;

Pituitary Foundation website: <http://www.pituitary.org.uk>

Types of evidence and the grading of recommendations

The definition of types of evidence and the grading of recommendations used in the guidelines follows that of the Agency for Health Care Policy and Research (AHCPR)¹, as set out below:

Type of evidence (based on AHCPR, 1992)¹

Level	Type of evidence
Ia	Evidence obtained from meta-analysis of randomized controlled trials.
Ib	Evidence obtained from at least one randomized controlled trial.
IIa	Evidence obtained from at least one well-designed controlled study without randomization.
IIb	Evidence obtained from at least one other type of well-designed quasi-experimental study.
III	Evidence obtained from well-designed nonexperimental descriptive studies, such as comparative studies, correlation studies and case control studies.
IV	Evidence obtained from expert committee reports or opinions and/or clinical experience of respected authorities.

Grading of recommendations (based on AHCPR, 1994)¹

Grade	Evidence levels	Description
A	I a, I b	Requires at least one randomized controlled trial as part of the body of literature of over all good quality and consistency addressing the specific recommendation.
B	II a, II b, III	Requires availability of well-conducted clinical studies but no randomized clinical trials on the topic of recommendation.
C	IV	Requires evidence from expert committee reports or opinions and/or clinical experience of respected authorities. Indicates absence of directly applicable studies of good quality
✓		Good practice point recommended by guideline development group

Convention for describing type of evidence and grade of recommendation

- The AHCPR level of evidence is included both in the main text and in the recommendations of sections 2–7 as bold roman numerals I–IV in parentheses (e.g. **III**).
- All recommendations in the guidelines are presented as bullet points with italic text. At the end of each recommendation, the AHCPR level of evidence is included and the corresponding grade of recommendation is included as a bold capital letter A–C in parentheses (e.g. **III, B**).

Introduction and rationale for guidelines

Pituitary apoplexy is a rare emergency that occurs in a small but significant number of patients who are harbouring a pituitary tumour, most often a clinically nonfunctioning macroadenoma. Most series indicate that the incidence of apoplexy in pituitary adenomas is between 2% and 7% when defined on the basis of clinical signs coupled with surgical or histopathological evidence.^{2–4} In over 80% of patients, pituitary apoplexy is often the first presentation of the underlying pituitary tumour.^{5,6} Most patients present in the fifth or sixth decade and there is a slight male preponderance (1.6:1.0).^{5,7,8}

As there is often clinical unawareness of the presence of a pre-existing pituitary tumour, the diagnosis can often be difficult and delayed with a wide differential diagnosis. Patients may present as an emergency to different specialties, often where immediate access to neurosurgical, endocrine and ophthalmological expertise are not easily available. These factors can lead to diagnostic difficulties and delays resulting in significant morbidity and rarely mortality.

It is clear that there are uncertainties about many aspects of the management of pituitary apoplexy. Some clearly feel that immediate neurosurgical intervention is essential to improve patient outcomes, whilst others argue that a more conservative approach with neurosurgical intervention only in certain clear clinical circumstances provides similar outcomes. This clear divergence of views

of best practice in the management of pituitary apoplexy has emphasized the need for national guidelines. However, such guidelines do not exist in the United Kingdom, the nearest being the references given to pituitary apoplexy in guidelines for management of patients with pituitary tumours published by the Royal College of Physicians in 1997.⁹

Definition of pituitary apoplexy

Classical pituitary apoplexy refers to a clinical syndrome, characterized by sudden onset of headache, vomiting, visual impairment and decreased consciousness caused by haemorrhage and/or infarction of the pituitary gland. Pearce Bailey described the first case of pituitary tumour-associated haemorrhage in the year 1898.¹⁰ The term pituitary apoplexy was first coined by Brougham *et al.*¹¹ in 1950, in a case series of five patients. Apoplexy usually occurs in patients with pre-existing pituitary adenomas and evolves within hours or days.¹²

Asymptomatic pituitary haemorrhage and/or infarction ('subclinical pituitary apoplexy') may be detected on routine imaging or during histopathological examination. The frequency of subclinical haemorrhagic infarction is around 25%, but this does not constitute a diagnosis of pituitary apoplexy.^{13,14}

Precipitating factors

Precipitating factors have been identified in up to 40% of cases of pituitary apoplexy (Table 1).⁵ Hypertension was by far the commonest (26%) predisposing factor.^{3,5} Major surgery, especially coronary artery bypass grafting, can precipitate apoplexy.^{15,16} Patients undergoing cardiac surgery are at higher risk as a result of fluctuations in blood pressure caused by cardiac bypass and use of anticoagulant therapy.¹⁷ Pituitary apoplexy should therefore always be considered in patients who develop headache and neuro-ophthalmic symptoms following major surgery.

Dynamic testing of the pituitary gland using gonadotrophin-releasing hormone, thyrotrophin-releasing hormone, corticotrophin-releasing hormone and insulin tolerance test have all been reported to trigger apoplexy.^{18–22} Pituitary tumour apoplexy after pituitary tests occurred within 2 h in 83% and within 88 h in all patients.²³

Anticoagulation therapy,²⁴ coagulopathies,²⁵ initiation or withdrawal of dopamine receptor agonists,²⁶ oestrogen therapy,²⁷ radiation therapy,¹² pregnancy²⁸ and head trauma²⁹ are some of the other factors known to instigate pituitary apoplexy.

Pathophysiology of the clinical manifestations

The clinical manifestations of pituitary apoplexy are because of a rapid increase in size of the intrasellar contents, leading to increase in the intrasellar pressure.³⁰ The earliest and the most common symptom (up to 100%) of pituitary apoplexy is sudden, severe headache.^{2,3,5,31} Headache is usually retroorbital, but can be bifrontal or diffuse and may be accompanied by nausea and vomiting. Lateral compression can affect the contents of the cavernous sinus leading to ocular palsies in nearly 70% of the patients.^{3,32,33} Third

Table 1. Precipitating factors in pituitary apoplexy

Systemic hypertension (26%)
Major surgery, in particular coronary artery bypass surgery
Dynamic pituitary function tests with GnRH, TRH and CRH
Anticoagulation therapy
Coagulopathies
Oestrogen therapy
Initiation or withdrawal of dopamine receptor agonist
Radiation therapy
Pregnancy
Head trauma

cranial (oculomotor) nerve is the most common nerve to be affected in nearly 50% of the patients with cranial nerve palsies.^{3–6} Decreased visual acuity and visual field defects, specifically bitemporal hemianopia, are seen in nearly 75% of the patients and are caused by upward enlargement of the intrasellar contents, leading to optic chiasmal compression.^{3–6} Extravasation of blood or necrotic tissue into the subarachnoid space can cause meningism resulting in fever, photophobia and altered consciousness level. Rarely, cerebral ischaemia can result from either mechanical compression of the carotid artery against the anterior clinoid or vasospasm secondary to subarachnoid haemorrhage.³⁴

Initial clinical, endocrine and radiological assessment

Clinical assessment

Clinical presentation can be either acute or subacute, with slow development of symptoms and signs and this is largely determined by the extent of haemorrhage, oedema and necrosis. As stated earlier, pituitary apoplexy most frequently occurs in a patient with an undiagnosed pituitary tumour. Furthermore, the clinical symptoms mimic other common neurological emergencies such as subarachnoid haemorrhage, bacterial meningitis or stroke leading to delayed or even a missed diagnosis. Therefore, a high degree of clinical suspicion is needed to diagnose pituitary apoplexy.

- A diagnosis of pituitary apoplexy should be considered in all patients presenting with acute severe headache with or without neuro-ophthalmic signs; (✓)
- Patients who have been diagnosed with pituitary tumour should be given clear information regarding the signs and symptoms of pituitary apoplexy and the precipitating factors; (✓)
- Patients known to have a pituitary tumour must be observed for signs and symptoms of pituitary apoplexy when performing pituitary stimulation tests, commencing anticoagulation therapy or undertaking coronary artery bypass or other major surgery; (IV, C)
- Initial assessment of the patients presenting with symptoms consistent with pituitary apoplexy should include a detailed history focusing on symptoms of pituitary dysfunction e.g. symptoms of hypogonadism, followed by a thorough physical examination including cranial nerves and visual fields to confrontation; (✓)
- Formal visual fields assessment, using Humphrey visual field analyzer or Goldmann perimeter must be undertaken when the patient is clinically stable, preferably within 24 h of the suspected diagnosis; (✓)

- *In haemodynamically unstable patients, in whom standard supportive measures are required to ensure haemodynamic stability, intravenous hydrocortisone should be administered after drawing blood samples for baseline endocrine function tests including random serum cortisol, free thyroxine (FT4) and thyrotrophin (TSH) (IV, C)*

Endocrine assessment

The majority of the patients (nearly 80%) will have deficiency of one or more anterior pituitary hormones at presentation.^{2–5,32} As most of the patients have underlying macroadenomas, partial hypopituitarism would be expected to have been present in the majority even before the apoplectic episode.^{3,5,36}

Clinically, the most crucial deficit is that of adrenocorticotroph hormone (ACTH) and has been reported in up to 70% of the patients.^{3,5,32} Thyrotrophin and gonadotrophin deficiencies are observed in 50% and 75% of the patients, respectively.^{3,5,32} Hyponatremia has been reported in up to 40% of the patients because of either the syndrome of inappropriate antidiuretic hormone secretion or hypocortisolism.³ Patients with pituitary apoplexy who have low serum prolactin (PRL) levels at presentation have the highest intrasellar pressure and are the least likely to recover from hypopituitarism after decompressive surgery.³⁰

- *All patients with suspected pituitary apoplexy should have urgent blood samples drawn to check electrolytes, renal function, liver function, clotting screen, full blood count, and random cortisol, PRL, FT4, TSH, insulin-like growth factor 1 (IGF1), growth hormone (GH), luteinizing hormone (LH), follicle-stimulating hormone (FSH) and testosterone in men, oestradiol in women. (IV, C)*

Radiological assessment

Magnetic resonance imaging (MRI) is the radiological investigation of choice and had been found to confirm the diagnosis of pituitary apoplexy in over 90% of the patients.^{2–5,32} Urgent referral is necessary when vision is deteriorating. However, computerized tomography (CT) is the most commonly used imaging modality in an acute clinical setting as it is readily available. CT scan was diagnostic in only 21–28% of cases, although a sellar mass was shown in up to 80% of the patients.^{4,5,32,37} MRI and MR angiogram techniques also help to distinguish an aneurysm from pituitary apoplexy.

- *Urgent MRI scan must be done in all patients with suspected pituitary apoplexy to confirm the diagnosis; (III, B)*
- *A dedicated pituitary CT scan is indicated if the MRI scan is either contraindicated or not possible; (IV, C)*
- *The results of the MRI or CT scan should be clearly explained to the patient as soon as possible after the investigation. (✓)*

Management

Steroid therapy in pituitary apoplexy

Acute secondary adrenal insufficiency is seen in approximately two-thirds of patients with pituitary tumour apoplexy and is the

major source of mortality associated with the condition.^{3,5,32} Hypocortisolaemia renders the vasculature less responsive to the pressor effects of catecholamines, with resultant haemodynamic instability in many patients. The mechanisms of fluid and electrolyte disturbances are complex. Hypocortisolaemia augments vasopressin release from the posterior pituitary and has an inhibitory effect on water excretion.

In view of this, prompt corticosteroid replacement should be assumed to be necessary in anticipation of the subsequent availability of confirmatory tests in patients who are haemodynamically unstable or who have other symptoms or signs suggestive of hypoadrenalism. Patients with pituitary apoplexy are unwell, frequently with nausea and vomiting, so oral corticosteroid is not recommended in the acute setting. Hydrocortisone 100–200 mg as an intravenous bolus is appropriate followed either by 2–4 mg per hour by continuous intravenous infusion or by 50–100 mg six hourly by intramuscular injection. Given the saturation kinetics of cortisol binding globulin, intermittent intravenous injections of hydrocortisone are less favoured; much of the administered steroid will be filtered into the urine and not pharmacologically available. Once the patient has recovered from the acute episode, the hydrocortisone dose should be quickly tapered to a standard maintenance dose of 20–30 mg per day, orally usually in three divided doses. ACTH reserve should be reassessed 2–3 months after the episode of acute pituitary tumour apoplexy has resolved. Dexamethasone is not favoured as glucocorticoid replacement, although it may be used to reduce oedema as part of a nonsurgical strategy for the treatment of pituitary tumour apoplexy.

- *The immediate medical management of patients with pituitary apoplexy should include careful assessment of fluid and electrolyte balance, replacement of corticosteroids and supportive measures to ensure haemodynamic stability; (III, B)*
- *Patients with pituitary apoplexy who are haemodynamically unstable should be commenced on empirical steroid therapy. In adults hydrocortisone 100–200 mg as an intravenous bolus is appropriate, followed either by 2–4 mg per hour by continuous intravenous infusion or by 50–100 mg six hourly by intramuscular injection, after drawing blood samples for random cortisol, FT4, TSH, PRL, IGF1, GH, LH, FSH, testosterone in men, oestradiol in women, electrolytes, renal function, liver function, full blood count and clotting screen; (IV, C)*
- *Indications for empirical steroid therapy in patients with pituitary apoplexy are haemodynamic instability, altered consciousness level, reduced visual acuity and severe visual field defects; (IV, C)*
- *Patients who do not fulfil the criteria for urgent empirical steroid therapy should be considered for treatment with steroids, if their 09:00 serum cortisol is less than 550 nmol/l; (IV, C)*
- *Further neuro-ophthalmic assessments to check the visual acuity, visual fields and ocular paresis must be undertaken, when the patient is clinically stable. (✓)*

Where should patients with pituitary apoplexy be managed?

Patients may present to medical or surgical emergency teams with signs and symptoms that mimic a wide differential diagnosis.

- *Once the diagnosis has been confirmed, it is recommended that all patients be transferred once medically stabilized following liaison and advice from the specialist neurosurgical/endocrine team to the local neurosurgical/endocrine team as soon as possible. Neurosurgical high dependency unit (HDU) facilities must be available. This team must have access to specialist endocrine and ophthalmological expertise. (✓)*

Surgery or conservative management?

The principle controversy in management relates to the role and the timing of neurosurgical decompression. Owing to the rarity of the condition there are no randomized controlled trials in the literature but several case series and reports. Early decompression has been suggested in a few retrospective observational studies, the rationale being the possibility of better visual and endocrine outcome.^{2,3}

Recent uncontrolled, retrospective studies have suggested that the endocrine and the visual outcome were no different between patients managed conservatively or by early surgical intervention.^{5,32,38} However, studies looking at the role of conservative versus surgical management of apoplexy with regard to visual loss all suffer from selection bias and a lack of appropriately matched patients. In most series, patients in the conservative group had less visual field/acuity loss than in the surgically treated group. Attempts have been also made to factor imaging characteristics into the decision-making process.³⁹ Uncontrolled data have indicated that a single large hypodense area within the tumour (as opposed to several small hypodense areas) was associated with subsequent tumour resolution.⁴⁰ Others have suggested that radiological evidence of early involution provides reassurance for a conservative strategy, emphasizing that the risk of CSF rhinorrhea, permanent diabetes insipidus and removal of normal anterior pituitary during surgery does not justify a surgical strategy over an initially conservative approach.

The difficulty in the management of pituitary apoplexy is to decide whether the clinical situation is appropriate for surgical intervention. Although there is a general consensus that a patient with apoplexy and significant neuro-ophthalmic signs or reduced level of consciousness should have surgical decompression, it is unclear what criteria define a significant neuro-ophthalmic deficit. There are no evidence-based criteria to justify the clinical decision between a conservative approach and neurosurgical intervention.

- *Patients with pituitary apoplexy should first be stabilized medically with steroid replacement if needed; (✓)*
- *The decision to manage conservatively or with surgical intervention should be made carefully by a multidisciplinary team, including experts in neurosurgery, endocrinology and ophthalmology; (✓)*
- *The rationale behind the clinical decisions should be fully explained to the patient and when possible their informed consent should be obtained; (✓)*
- *Leaflets explaining the diagnosis of pituitary tumours and pituitary apoplexy should be provided to the patient. (✓)*

Indications for conservative management

Recent retrospective studies have confirmed that mild neuro-ophthalmic signs tend to improve spontaneously in most

patients with pituitary apoplexy who are managed conservatively.^{5,32,38} The capricious nature of pituitary apoplexy makes it impossible to exclude patients from surgical intervention by speculating that their conditions will remain stable. Hence, patients who are conservatively managed initially should be closely monitored, and surgical intervention must be considered if neuro-ophthalmic signs fail to improve or deteriorate. Further assessment of the patient with conservatively treated pituitary apoplexy should include a daily clinical and neurological examination including cranial nerves and visual fields as well as assessment of visual acuity.

- *Patients with pituitary apoplexy who are without any neuro-ophthalmic signs or mild and stable signs can be considered for conservative management with careful monitoring. (III, B)*
- *In patients with reduced visual acuity or defective visual fields, formal assessment of visual fields and acuity should be performed every day until a clear trend of improvement is observed. (✓)*
- *Acutely unwell patients should have neurological assessment every hour and any deterioration in neurological status should prompt urgent senior medical review with consideration to proceed with surgery; (✓)*
- *The frequency of neurological assessment could be gradually reduced to every 4–6 h, when the patients are stable; (✓)*
- *Renal functions and electrolytes should be checked daily. Further, endocrine specialist evaluation to assess possible under or over secretion of pituitary hormones should be undertaken in stable patients. (✓)*

Indications for surgical management

One of the most extensive surveys of pituitary apoplexy from a single centre (Oxford, UK) has reported significantly greater improvement in visual acuity and visual field defects (but not ocular paresis) in patients who had early (within 8 days) surgery.³ A decision regarding the timing of the surgery should be based on the severity and the progression of the signs and symptoms.

Semi-elective transsphenoidal surgery should be considered for patients who are clinically stable, but show no improvement or deterioration in the neuro-ophthalmic signs. Such an approach would enable the surgery to be performed by the pituitary surgeon, rather than by the on call neurosurgical team. Surgery should be performed by an experienced pituitary surgeon defined as an experience of five or more transsphenoidal pituitary operations per annum. If not available, consideration should be given to transfer to nearest available Neurosurgical Unit.

- *Patients with severe neuro-ophthalmic signs such as severely reduced visual acuity, severe and persistent or deteriorating visual field defects or deteriorating level of consciousness should be considered for surgical management; (III, B)*
- *Ocular paresis because of involvement of III, IV or VI cranial nerves in the cavernous sinus in the absence of visual field defects or reduced visual acuity is not in itself an indication for immediate surgery. Resolution will typically occur within days or weeks with conservative management; (III, B)*
- *We would recommend the surgery to be performed by an experienced pituitary surgeon rather than by the on call neurosurgical*

team unless the clinical situation warrants immediate intervention; (IV, C)

- *Surgery should be performed preferably within the first 7 days of onset of symptoms. (III, B)*

The indications for surgery in those initially managed conservatively

If there is no indication for initial operative management, it is rare to change from a conservative to an operative course.^{5,38} However, there is evidence that patients in whom there is no response to steroid therapy after 1 week may also benefit from delayed surgical intervention.⁴⁰

- *The presence of a new or deteriorating visual deficit or neurological deterioration should prompt further urgent imaging with a view to decompressive surgery (including external ventricular drain (EVD) placement in the presence of hydrocephalus). (IV, C)*

Postoperative care

Immediate postoperative care

The postoperative management of patients following surgery for pituitary apoplexy is similar to that of elective pituitary surgery for pituitary tumours. However, most patients with pituitary apoplexy may not have had a full endocrine work-up prior to the operation, and hence it is essential to monitor them more closely during the immediate postoperative period.

Transient diabetes insipidus is noted postoperatively in up to 16% of the patients with pituitary apoplexy during their hospital stay.³ Other potential postoperative complications include cortisol deficiency, visual loss, cerebrospinal fluid leakage and meningitis.

- *Patients should be reviewed every hour to assess the fluid balance and serum urea, serum creatinine, serum electrolytes, plasma & urine osmolalities should be checked immediately if diabetes insipidus is suspected; (IV, C)*
- *Other postoperative complications such as cerebrospinal fluid leakage, visual loss, meningitis and cortisol deficiency should be proactively looked out for; (IV, C)*
- *Full blood count, serum urea, serum creatinine, serum electrolytes, and plasma/urine osmolalities should be checked at least once daily or more frequently if there are clinical concerns. (IV, C)*

Endocrine assessment

Evaluation of steroid reserve and thyroid functions should be undertaken carefully during the postoperative period. The short synacthen test would be highly unreliable in the immediate postoperative period and hence the 09:00 serum cortisol is initially used to assess the steroid status (see Table 2). This is based on an audit of postoperative cortisol values and subsequent dynamic tests of ACTH reserve carried out in Oxford (47). Cortisol values should be interpreted with caution in women, who have stopped oestrogen replacement therapy <6 weeks before surgery, because of the confounding effect of raised cortisol binding globulin levels.

Table 2. Postoperative hydrocortisone in patients without Cushing's disease

9 a.m. cortisol level	Action
>550 nmol/l	No requirement for hydrocortisone
400–550 nmol/l	Hydrocortisone only during severe illness or stress*
<400 nmol/l	Start regular oral hydrocortisone

*Give patient supply of oral and parenteral hydrocortisone to take home with appropriate written advice⁴⁷

Thyroid function (FT4 and TSH) should be tested on day three or on day four after surgery. Thyroid function can be normal in the immediate postoperative period, and hence it is important to test again at 4–8 weeks postoperatively. Sick euthyroid syndrome can sometimes complicate the biochemical picture and affect the interpretation of thyroid function test results.

If pre-operative steroid reserve adequate or unknown:

- *Check 9 am serum cortisol on day two and day three after surgery, in patients with no evidence of cortisol deficiency before operation. If already on hydrocortisone replacement, omit the evening dose for the previous day before checking. (IV, C)*

If pre-operative steroid reserve deficient:

- *In patients with proven cortisol deficiency before surgery, continue hydrocortisone and consider changing over to maintenance dosage when stable. These patients will need further assessment at 4–8 weeks to determine whether they will need long-term steroids; (IV, C)*
- *FT4 and TSH should be assessed on day three or day four, and thyroid hormone replacement should be considered if deficient; (IV, C)*
- *If FT4 and TSH normal further assessment should take place at 4–8 weeks. (IV, C)*

Visual assessment

- *Visual acuity, eye movements and visual fields should be examined at the bedside preferably within 48 h and this should be followed by formal visual field assessment using Humphrey visual field analyzer or Goldmann perimeter; (IV, C)*
- *Patients who develop unexpected visual loss or significant deterioration in the visual fields should have urgent MRI scan and a review by the Neurosurgical team. (✓)*

Long-term follow-up and outcomes

Endocrine outcomes

Studies have shown partial or complete recovery of pituitary function in up to 50% of patients.^{30,41} Early studies showed a better chance for improvement in pituitary function in surgically managed patients.⁴¹ More recent retrospective studies found no statistically significant differences in the endocrine outcome between the surgically and conservatively managed patients.^{32,38}

Nearly 80% of the patients will need some form of hormone replacement after apoplexy.^{3,32,38} Growth hormone deficiency is the most commonly observed deficit after apoplexy and is present

in almost all patients but rarely replaced.⁴² The data suggest that long-term hormone replacement therapy following pituitary apoplexy is corticosteroids in 60–80%, thyroid hormone in 50–60%, desmopressin in 10–25% of patients and testosterone in 60–80% of men.^{3,32,38}

- All patients with pituitary apoplexy should have an endocrine review at 4–8 weeks following the event. They should have full biochemical assessment of pituitary function and formal assessment of their visual acuity, eye movements and visual fields; (✓)
- Patients treated for apoplexy should have an annual biochemical assessment of pituitary function which should include FT4, TSH, LH, FSH, testosterone in men, oestradiol in women, prolactin, IGF1 and dynamic tests of cortisol and growth hormone secretion if clinically appropriate. (IV, C)

Visual outcomes

Visual acuity, visual field defects and ophthalmoplegia have been reported to improve in the majority of the patients after surgical decompression.^{2–4,43} Such improvement is observed in the immediate postoperative period and often continues for several weeks after surgery.⁴⁴ Visual recovery is less likely in patients presenting with monocular or binocular blindness.³⁸ However, significant improvement has been observed in patients rendered blind by pituitary apoplexy if early surgical decompression was undertaken.⁴⁵ Recent studies have reported a better visual outcome in conservatively managed patients but as mentioned earlier, these studies have a selection bias from inappropriately matched patients.

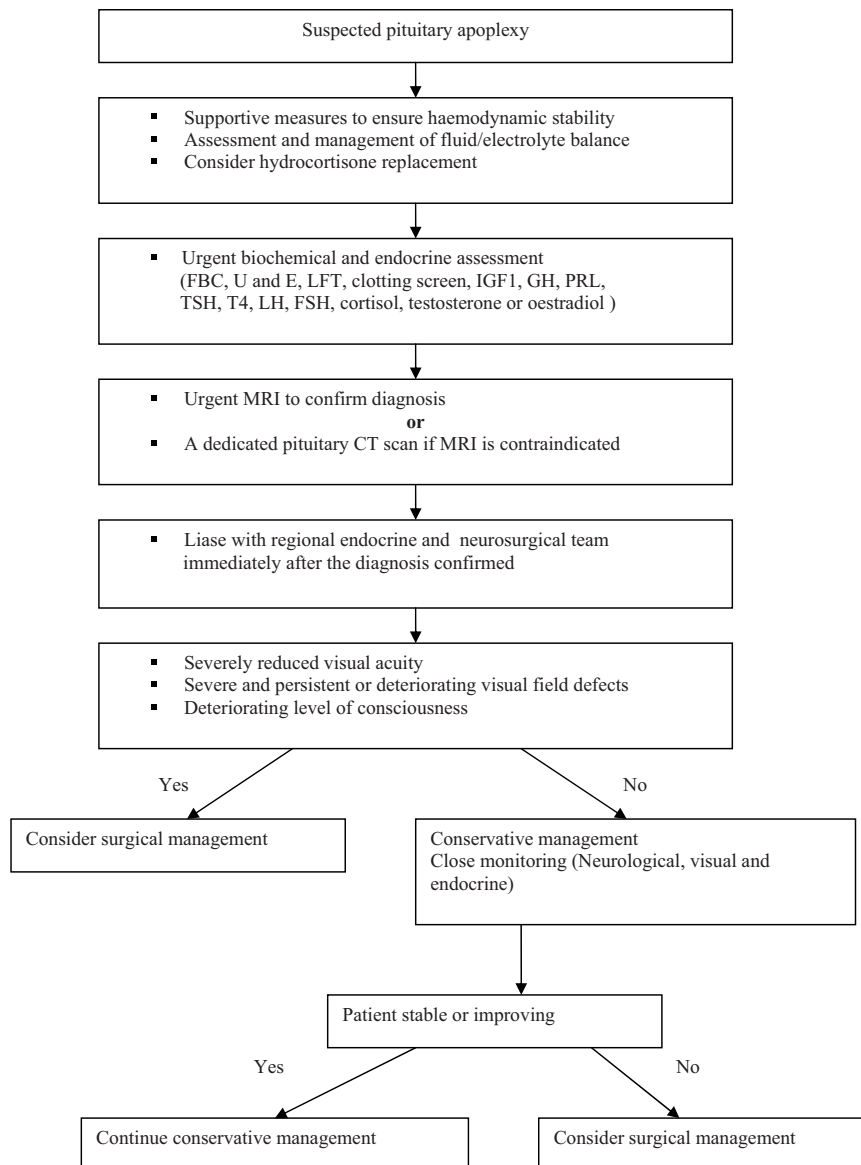


Fig. 1 Algorithm for the management of pituitary apoplexy.

Long-term monitoring and surveillance

Recurrent apoplexy and tumour regrowth has been documented both in surgically and conservatively managed group of patients. Earlier studies showed a slightly increased incidence of recurrent apoplexy in conservatively managed patients.^{11,12,46} However, recent studies have not shown significant differences between these groups.^{32,38} Therefore, all patients who have been treated for apoplexy need long-term follow-up imaging to detect recurrent growth. Long-term management depends on the nature of the underlying pituitary tumour.

- Both conservatively and surgically treated patients need close radiological follow-up and if residual tumour or recurrence is detected, additional modalities such as radiotherapy or redo surgery should be considered; (III, B)
- A MRI scan is recommended at 3–6 months after apoplexy and thereafter an annual MRI scan should be considered for the next 5 years, then two yearly; (IV, C)
- All patients require at least an annual clinical review preferably in a joint endocrine/neurosurgical clinic. It is recommended that all patients be discussed within the pituitary multidisciplinary team; (✓)
- There should be recognition of the psychological aspects of pituitary disease and support from endocrine specialist nurse and patient support organizations like The Pituitary Foundation should be provided where appropriate. (✓)

Areas for audit

The evidence on which many of our recommendations have been made is weak because of a lack of randomized studies. There are no clear criteria to define a significant neuro-ophthalmic deficit. We also need an effective tool to monitor patients managed conservatively. An algorithm based upon these management guidelines is shown in Fig. 1. A scoring system has been

Table 3. Pituitary Apoplexy score

Variable	Points
Level of Consciousness	
Glasgow coma scale 15	0
Glasgow coma scale <8–14	2
Glasgow coma scale <8	4
Visual acuity	
Normal* 6/6	0
Reduced – unilateral	1
bilateral	2
Visual field defects	
Normal	0
Unilateral defect	1
Bilateral defect	2
Ocular paresis	
Absent	0
Present – Unilateral	1
Bilateral	2

*No change from premorbid visual acuity.

designed which could serve as a uniform tool to monitor the conservatively managed patients (See Table 3). The scoring system would help to quantify the neuro-ophthalmic deficits and audit the outcome in surgically and conservatively managed patients.

Following an initial national audit of patient outcomes, the long-term aim is to set up a randomized controlled clinical trial of conservative versus surgical intervention in patients with pituitary apoplexy which would help to refine these management guidelines.

References

- 1 Atkins, D., Eccles, M., Flottorp, S. *et al.* (2004) Systems for grading the quality of evidence and the strength of recommendations I: Critical appraisal of existing approaches The GRADE Working Group. *BMC Health Services Research*, **4**, 38.
- 2 Bills, D.C., Meyer, F.B., Laws Jr, E.R. *et al.* (1993) A retrospective analysis of pituitary apoplexy. *Neurosurgery*, **33**, 602–608; discussion 608–9.
- 3 Randeve, H.S., Schoebel, J., Byrne, J. *et al.* (1999) Classical pituitary apoplexy: clinical features, management and outcome. *Clinical Endocrinology (Oxf)*, **51**, 181–188.
- 4 Onesti, S.T., Wisniewski, T. & Post, K.D. (1990) Clinical versus subclinical pituitary apoplexy: presentation, surgical management, and outcome in 21 patients. *Neurosurgery*, **26**, 980–986.
- 5 Sibal, L., Ball, S.G., Connolly, V. *et al.* (2004) Pituitary apoplexy: a review of clinical presentation, management and outcome in 45 cases. *Pituitary*, **7**, 157–163.
- 6 Semple, P.L., Jane Jr, J.A. & Laws Jr, E.R. (2007) Clinical relevance of precipitating factors in pituitary apoplexy. *Neurosurgery*, **61**, 956–961. discussion 961–2.
- 7 Reid, R.L., Quigley, M.E. & Yen, S.S. (1985) Pituitary apoplexy. A review. *Archives of Neurology*, **42**, 712–719.
- 8 McFadzean, R.M., Doyle, D., Rampling, R. *et al.* (1991) Pituitary apoplexy and its effect on vision. *Neurosurgery*, **29**, 669–675.
- 9 Clayton, R.N. & Wass, J.A.H. (1997) Pituitary tumours: recommendations for service provision and guidelines for management of patients. Summary of a consensus statement of a working party from the Endocrinology and Diabetes Committee of The Royal College of Physicians and the Society for Endocrinology in conjunction with the Research Unit of the Royal College of Physicians. *Journal of the Royal College of Physicians of London*, **31**, 628–636.
- 10 Bailey, P. (1898) Pathological report of a case of acromegaly, with special reference to the lesions in the hypophysis cerebri and in the thyroid gland; and a case of haemorrhage in to the pituitary. *Philadelphia medical journal*, **1**, 789–792.
- 11 Brougham, M., Heusner, A.P. & Adams, R.D. (1950) Acute degenerative changes in adenomas of the pituitary body—with special reference to pituitary apoplexy. *Journal of Neurosurgery*, **7**, 421–439.
- 12 Weisberg, L.A. (1977) Pituitary apoplexy. Association of degenerative change in pituitary adenoma with radiotherapy and detection by cerebral computed tomography. *American Journal of Medicine*, **63**, 109–115.
- 13 Bonicki, W., Kasperlik-Zaluska, A., Koszewski, W. *et al.* (1993) Pituitary apoplexy: endocrine, surgical and oncological emergency. Incidence, clinical course and treatment with reference to 799 cases of pituitary adenomas. *Acta Neurochirurgica (Wien)*, **120**, 118–122.
- 14 Mohr, G. & Hardy, J. (1982) Hemorrhage, necrosis, and apoplexy in pituitary adenomas. *Surgical Neurology*, **18**, 181–189.

- 15 Abbott, J. & Kirkby, G.R. (2004) Acute visual loss and pituitary apoplexy after surgery. *BMJ*, **329**, 218–219.
- 16 Alzetani, A., Fisher, C., Costa, R. *et al.* (2002) Ptosis postcardiac surgery: a case of pituitary apoplexy. *Annals of Thoracic Surgery*, **73**, 300–301.
- 17 Pliam, M.B., Cohen, M., Cheng, L. *et al.* (1995) Pituitary adenomas complicating cardiac surgery: summary and review of 11 cases. *Journal of Cardiac Surgery*, **10**, 125–132.
- 18 Arafah, B.M., Taylor, H.C., Salazar, R. *et al.* (1989) Apoplexy of a pituitary adenoma after dynamic testing with gonadotropin-releasing hormone. *American Journal of Medicine*, **87**, 103–105.
- 19 Masson, E.A., Atkin, S.L., Diver, M. *et al.* (1993) Pituitary apoplexy and sudden blindness following the administration of gonadotrophin releasing hormone. *Clinical Endocrinology (Oxf)*, **38**, 109–110.
- 20 Matsuura, I., Saeki, N., Kubota, M. *et al.* (2001) Infarction followed by hemorrhage in pituitary adenoma due to endocrine stimulation test. *Endocrine Journal*, **48**, 493–498.
- 21 Lee, D.H., Chung, M.Y., Chung, D.J. *et al.* (2000) Apoplexy of pituitary macroadenoma after combined test of anterior pituitary function. *Endocrine Journal*, **47**, 329–333.
- 22 Levy, A. (2003) Hazards of dynamic testing of pituitary function. *Clinical Endocrinology (Oxf)*, **58**, 543–544.
- 23 Yoshino, A., Katayama, Y., Watanabe, T. *et al.* (2007) Apoplexy accompanying pituitary adenoma as a complication of preoperative anterior pituitary function tests. *Acta Neurochirurgica (Wien)*, **149**, 557–565; discussion 565.
- 24 Nagarajan, D.V., Bird, D. & Papouchado, M. (2003) Pituitary apoplexy following anticoagulation for acute coronary syndrome. *Heart*, **89**, 10.
- 25 Maiza, J.C., Bennet, A., Thorn-Kany, M. *et al.* (2004) Pituitary apoplexy and idiopathic thrombocytopenic purpura: a new case and review of the literature. *Pituitary*, **7**, 189–192.
- 26 Knoepfelmacher, M., Gomes, M.C., Melo, M.E. *et al.* (2004) Pituitary apoplexy during therapy with cabergoline in an adolescent male with prolactin-secreting macroadenoma. *Pituitary*, **7**, 83–87.
- 27 Cardoso, E.R. & Peterson, E.W. (1984) Pituitary apoplexy: a review. *Neurosurgery*, **14**, 363–373.
- 28 de Heide, L.J., van Tol, K.M. & Doorenbos, B. (2004) Pituitary apoplexy presenting during pregnancy. *Netherlands Journal of Medicine*, **62**, 393–396.
- 29 Holness, R.O., Ogundimu, F.A. & Langille, R.A. (1983) Pituitary apoplexy following closed head trauma. Case report. *Journal of Neurosurgery*, **59**, 677–679.
- 30 Zayour, D.H., Selman, W.R. & Arafah, B.M. (2004) Extreme elevation of intrasellar pressure in patients with pituitary tumor apoplexy: relation to pituitary function. *Journal of Clinical Endocrinology and Metabolism*, **89**, 5649–5654.
- 31 Biousse, V., Newman, N.J. & Oyesiku, N.M. (2001) Precipitating factors in pituitary apoplexy. *Journal of Neurology, Neurosurgery and Psychiatry*, **71**, 542–545.
- 32 Ayuk, J., McGregor, E.J., Mitchell, R.D. *et al.* (2004) Acute management of pituitary apoplexy—surgery or conservative management? *Clinical Endocrinology (Oxf)*, **61**, 747–752.
- 33 Lubina, A., Olchovsky, D., Berezin, M. *et al.* (2005) Management of pituitary apoplexy: clinical experience with 40 patients. *Acta Neurochirurgica (Wien)*, **147**, 151–157. discussion 157.
- 34 Ahmed, S.K. & Semple, P.L. (2008) Cerebral ischaemia in pituitary apoplexy. *Acta Neurochirurgica (Wien)*, **150**, 1193–1196. discussion 1196.
- 35 Arafah, B.M. (1986) Reversible hypopituitarism in patients with large nonfunctioning pituitary adenomas. *Journal of Clinical Endocrinology and Metabolism*, **62**, 1173–1179.
- 36 Arafah, B.M., Kailani, S.H., Nekl, K.E. *et al.* (1994) Immediate recovery of pituitary function after transsphenoidal resection of pituitary macroadenomas. *Journal of Clinical Endocrinology and Metabolism*, **79**, 348–354.
- 37 Kaplan, B., Day, A.L., Quisling, R. *et al.* (1983) Hemorrhage into pituitary adenomas. *Surgical Neurology*, **20**, 280–287.
- 38 Gruber, A., Clayton, J., Kumar, S. *et al.* (2006) Pituitary apoplexy: retrospective review of 30 patients—is surgical intervention always necessary? *British Journal of Neurosurgery*, **20**, 379–385.
- 39 Piotin, M., Tampieri, D., Rufenacht, D.A. *et al.* (1999) The various MRI patterns of pituitary apoplexy. *European Radiology*, **9**, 918–923.
- 40 Maccagnan, P., Macedo, C.L., Kayath, M.J. *et al.* (1995) Conservative management of pituitary apoplexy: a prospective study. *Journal of Clinical Endocrinology and Metabolism*, **80**, 2190–2197.
- 41 Arafah, B.M., Harrington, J.F., Madhoun, Z.T. *et al.* (1990) Improvement of pituitary function after surgical decompression for pituitary tumor apoplexy. *Journal of Clinical Endocrinology and Metabolism*, **71**, 323–328.
- 42 Veldhuis, J.D. & Hammond, J.M. (1980) Endocrine function after spontaneous infarction of the human pituitary: report, review, and reappraisal. *Endocrine Reviews*, **1**, 100–107.
- 43 Dubuisson, A.S., Beckers, A. & Stevenaert, A. (2007) Classical pituitary tumour apoplexy: clinical features, management and outcomes in a series of 24 patients. *Clinical Neurology and Neurosurgery*, **109**, 63–70.
- 44 Kerrison, J.B., Lynn, M.J., Baer, C.A. *et al.* (2000) Stages of improvement in visual fields after pituitary tumor resection. *American Journal of Ophthalmology*, **130**, 813–820.
- 45 Muthukumar, N., Rossette, D., Soundaram, M. *et al.* (2008) Blindness following pituitary apoplexy: timing of surgery and neuro-ophthalmic outcome. *Journal of Clinical Neuroscience*, **15**, 873–879.
- 46 Conomy, J.P., Ferguson, J.H., Brodkey, J.S. *et al.* (1975) Spontaneous infarction in pituitary tumors: neurologic and therapeutic aspects. *Neurology*, **25**, 580–587.
- 47 Walker, J.N., Nickerson, E., Gardner, S.G. *et al.* Should post hypophysectomy patients be discharged on steroids? The use of 0900h-cortisol measurements as a screening test for pituitary-adrenal dysfunction

Appendix 1. Summary of recommendations

Clinical assessment

- A diagnosis of pituitary apoplexy should be considered in all patients presenting with acute severe headache with or without neuro-ophthalmic signs; (✓)
- Patients who have been diagnosed with pituitary tumour should be given clear information regarding the signs and symptoms of pituitary apoplexy and the precipitating factors; (✓)
- Patients known to have a pituitary tumour must be observed for signs and symptoms of pituitary apoplexy when performing pituitary stimulation tests, commencing anticoagulation therapy or undertaking coronary artery bypass or other major surgery; (IV, C)

- Initial assessment of the patients presenting with symptoms consistent with pituitary apoplexy should include a detailed history focusing on symptoms of pituitary dysfunction e.g. symptoms of hypogonadism, followed by a thorough physical examination including cranial nerves and visual fields to confrontation; (✓)
- Formal visual fields assessment using Humphrey visual field analyzer or Goldmann perimeter must be undertaken when the patient is clinically stable, preferably within 24 h of suspected diagnosis; (✓)
- In haemodynamically unstable patients, in whom standard supportive measures are required to ensure haemodynamic stability, intravenous hydrocortisone should be administered after drawing blood samples for baseline endocrine function tests including random serum cortisol, FT4 and TSH. (IV, C)

Endocrine assessment

- All patients with suspected pituitary apoplexy should have urgent blood samples drawn to check electrolytes, renal function, liver function, clotting screen, full blood count, and random cortisol, PRL, FT4, TSH, IGF1, GH, LH, FSH and testosterone in men, oestradiol in women. (IV, C)

Radiological assessment

- Urgent MRI scan must be done in all patients with suspected pituitary apoplexy to confirm the diagnosis; (III, B)
- A dedicated pituitary CT scan is indicated if the MRI scan is either contraindicated or not possible; (IV, C)
- The results of the MRI or CT scan should be clearly explained to the patient as soon as possible after the investigation. (✓)

Management

Steroid therapy in pituitary apoplexy

- The immediate medical management of patients with pituitary apoplexy should include careful assessment of fluid and electrolyte balance, replacement of corticosteroids and supportive measures to ensure haemodynamic stability; (III, B)
- Patients with pituitary apoplexy who are haemodynamically unstable should be commenced on empirical steroid therapy. In adults hydrocortisone 100–200 mg as an intravenous bolus is appropriate, followed either by 2–4 mg per hour by continuous intravenous infusion or by 50–100 mg six hourly by intramuscular injection, after drawing blood samples for random cortisol, FT4, TSH, PRL, IGF1, GH, LH, FSH, testosterone in men, oestradiol in women, electrolytes, renal function, liver function, full blood count and clotting screen; (IV, C)
- Indications for empirical steroid therapy in patients with pituitary apoplexy are haemodynamic instability, altered consciousness level, reduced visual acuity and severe visual field defects; (IV, C)
- Patients who do not fulfil the criteria for urgent empirical steroid therapy should be considered for treatment with steroids, if their 09:00 serum cortisol is less than 550 nmol/l; (IV, C)

- Further neuro-ophthalmic assessments to check the visual acuity, visual fields and ocular paresis must be undertaken, when the patient is clinically stable. (✓)

Where should patients with pituitary apoplexy be managed?

- Once the diagnosis has been confirmed, it is recommended that all patients be transferred once medically stabilized following liaison and advice from the specialist neurosurgical/endocrine team to the local neurosurgical/endocrine team as soon as possible. Neurosurgical HDU facilities must be available. This team must have access to specialist endocrine and ophthalmological expertise. (✓)

Surgery or conservative management?

- Patients with pituitary apoplexy should first be stabilized medically with steroid replacement if needed; (✓)
- The decision to manage conservatively or with surgical intervention should be made carefully by a multidisciplinary team, including experts in neurosurgery, endocrinology and ophthalmology; (✓)
- The rationale behind the clinical decisions should be fully explained to the patient and when possible their informed consent should be obtained; (✓)
- Leaflets explaining the diagnosis of pituitary tumours and pituitary apoplexy should be provided to the patient. (✓)

Indications for conservative management

- Patients with pituitary apoplexy who are without any neuro-ophthalmic signs or mild and stable signs can be considered for conservative management with careful monitoring; (III, B)
- In patients with reduced visual acuity or defective visual fields, formal assessment of visual fields and acuity should be performed every day until clear trend of improvement is observed; (✓)
- Acutely unwell patients should have neurological assessment every hour and any deterioration in neurological status should prompt urgent senior medical review with consideration to proceed with surgery; (✓)
- The frequency of neurological assessment could be gradually reduced to every 4–6 h, when the patients are stable; (✓)
- Renal function and electrolytes should be checked daily. Further endocrine specialist evaluation to assess possible under or over secretion of pituitary hormones should be undertaken in stable patients. (✓)

Indications for surgical management

- Patients with severe neuro-ophthalmic signs such as severely reduced visual acuity, severe and persistent or deteriorating visual field defects or deteriorating level of consciousness should be considered for surgical management; (III, B)
- Ocular paresis because of involvement of III, IV or VI cranial nerves in cavernous sinus in the absence of visual field defects or reduced visual acuity is not in itself an indication for immediate surgery.

Resolution will typically occur within days or weeks with conservative management; (III, B)

- We would recommend the surgery to be performed by an experienced pituitary surgeon rather than by the on call neurosurgical team unless if the clinical situation warrants immediate intervention; (IV, C)
- Surgery should be performed preferably within the first 7 days of onset of symptoms. (III, B)

The indications for surgery in those initially managed conservatively

- The presence of a new or deteriorating visual deficit or neurological deterioration should prompt further urgent imaging with a view to decompressive surgery (including external ventricular drain (EVD) placement in the presence of hydrocephalus). (IV, C)

Postoperative care

Immediate postoperative care

- Patients should be reviewed every hour to assess the fluid balance and serum urea, serum creatinine, serum electrolytes, plasma & urine osmolalities should be checked immediately if diabetes insipidus is suspected; (IV, C)
- Other postoperative complications such as cerebrospinal fluid leakage, visual loss, meningitis and cortisol deficiency should be proactively looked out for; (IV, C)
- Full blood count, serum urea, serum creatinine, serum electrolytes, and plasma/urine osmolalities should be checked at least once daily or more frequently if there are clinical concerns. (IV, C)

Endocrine assessment

If pre-operative steroid reserve adequate or unknown:

- Check 9 am serum cortisol on day two and on day three after surgery, in patients with no evidence of cortisol deficiency before operation. If already on hydrocortisone replacement, omit the evening dose for the previous day before checking. (IV, C)

If pre-operative steroid reserve deficient:

- In patients with proven cortisol deficiency before surgery, continue hydrocortisone and consider changing over to maintenance dosage when stable. These patients will need further assessment at 4–8 weeks to determine whether they will need long-term steroids; (IV, C)
- FT4 and TSH should be assessed on day three or day four and thyroid hormone replacement should be considered if deficient; (IV, C).
- If FT4 and TSH normal further assessment should take place at 4–8 weeks. (IV, C).

Visual assessment

- Visual acuity, eye movements and visual fields should be examined at the bedside preferably within 48 h, and this should be followed by

formal visual field assessment using Humphrey visual field analyzer or Goldmann perimeter; (IV, C)

- Patients who develop unexpected visual loss or significant deterioration in the visual fields should have urgent MRI scan and a review by the Neurosurgical team. (✓)

Long-term follow-up and outcomes

Endocrine outcomes

- All patients with pituitary apoplexy should have an endocrine review at 4–8 weeks following the event. They should have full biochemical assessment of pituitary function and formal assessment of their visual acuity, eye movements and visual fields; (✓)
- Patients treated for apoplexy should have an annual biochemical assessment of pituitary function which should include FT4, TSH, LH, FSH, testosterone in men, oestradiol in women, prolactin, IGF1 and dynamic tests of cortisol and growth hormone secretion if clinically appropriate. (IV, C)

Long-term monitoring and surveillance

- Both conservatively and surgically treated patients need close radiological follow-up and if residual tumour or recurrence is detected, additional modalities such as radiotherapy or redo surgery should be considered; (III, B)
- A MRI scan is recommended at 3–6 months after apoplexy and thereafter an annual MRI scan should be considered for the next 5 years, then two yearly; (IV, C)
- All patients require at least an annual clinical review preferably in a joint endocrine/neurosurgical clinic. It is recommended that all patients must be discussed within the pituitary multidisciplinary team; (✓)
- There should be recognition of the psychological effects of pituitary disease and support from an endocrine specialist nurse and patient support organizations like the Pituitary Foundation should be provided. (✓)

Appendix 2. Abbreviations

ACTH	Adrenocorticotrophic hormone
AHCPR	Agency for Health Care Policy and Research
CRH	Corticotrophin-releasing hormone
CSF	Cerebrospinal fluid
CT	Computerized tomographic
EVD	External ventricular drain
FBC	Full blood count
FSH	Follicle-stimulating hormone
FT4	Free thyroxine
FT3	Free tri-iodothyronine
GH	Growth hormone
GNRH	Gonadotrophin-releasing hormone
GP	General Practitioner
HDU	High dependency unit
IGF1	Insulin-like growth factor 1

Appendix 2. (Continued)

ITT	Insulin tolerance test
ITU	Intensive therapy unit
LFT	Liver function tests
LH	Luteinizing hormone
MRA	Magnetic resonance angiogram
MRI	Magnetic resonance imaging
mu/l	Milliunits per litre
nmol/l	Nanomoles per litre
pmol/l	Picomoles per litre
PRL	Prolactin
RCP	Royal College of Physicians
T4	Thyroxine, levothyroxine
T3	Tri-iodothyronine
TFT	Thyroid function tests
TRH	Thyrotrophin-releasing hormone
TSH	Thyroid-stimulating hormone, thyrotrophin
U & E	Urea, creatinine & electrolytes
µg	Microgram

Appendix 3. Acknowledgements

We are indebted to the following specialists for their very valuable comments on the guidelines:

Dr J Ayuk, Consultant Endocrinologist & Society for Endocrinology, Queen Elizabeth Hospital, Birmingham.

Prof M Besser, Professor of Endocrinology, The London Clinic Centre for Endocrinology.

Prof J Davis, Consultant Endocrinologist & Society for Endocrinology University of Manchester, Manchester.

Dr C Daousi, Consultant Endocrinologist, University Hospital Aintree.

Dr D. Fowler, Consultant Endocrinologist & Society for Endocrinology, Ipswich Hospital.

Prof. A. Grossman, Professor of Endocrinology & Society for Endocrinology, St Bartholomew's Hospital, London.

Dr M Gurnell, Consultant Endocrinologist & Society for Endocrinology, Addenbrooke's Hospital, Cambridge.

Dr N Gittoes, Consultant Endocrinologist & Society for Endocrinology, Queen Elizabeth Hospital, Birmingham.

Dr C Higgins, Consultant Physician & Society for Acute Medicine, Northwick Park Hospital, London on behalf of the Acute Medicine and GIM Committee of the Royal College of Physicians.

Dr D Jenkins, Consultant Endocrinologist & Society for Endocrinology, Worcestershire Royal Hospital.

Prof A Johnson, Chair of the ENT Surgeons.

Mr R Kirillos, Consultant Neurosurgeon & Society of British Neurological Surgeons, Addenbrooke's Hospital, Cambridge.

Dr G Leese, Consultant Endocrinologist & Society for Endocrinology Ninewells Hospital, Dundee.

Prof J P Monson, Professor of Endocrinology & Society for Endocrinology, The London Clinic Centre for Endocrinology.

Dr D Price, Consultant Endocrinologist & Society for Endocrinology, Morriston Hospital, Swansea.

Dr P Price, Consultant Endocrinologist & Society for Endocrinology, Great Western Hospital, Swindon.


Dr R Quinton, Consultant Endocrinologist & Society for Endocrinology, Royal Victoria Infirmary, Newcastle-upon-Tyne.

Mr M Radatz, Consultant Neurosurgeon & Society of British Neurological Surgeons, Royal Hallamshire Hospital, Sheffield.

Mr N Thomas, Consultant Neurosurgeon & Society of British Neurological Surgeons, King's college Hospital, London.

Prof P van Hille, President of the Society of British Neurological Surgeons.

Dr A. D. Platts, Consultant Neuro & Vascular Radiologist, Royal Free Hospital.



Society for Endocrinology

22 Apex Court, Bradley Stoke, Bristol BS32 4JT. United Kingdom

Copyright ©2011 Society for Endocrinology. Company Limited by Guarantee.
Registered in England No. 349408. Registered Charity No. 266813.