

Clinical Practice Guidelines for Multiple Endocrine Neoplasia Type 1 (MEN1)

Rajesh V. Thakker, Paul J. Newey, Gerard V. Walls, John Bilezikian, Henning Dralle, Peter R. Ebeling, Shlomo Melmed, Akihiro Sakurai, Francesco Tonelli, and Maria Luisa Brandi

Academic Endocrine Unit (R.V.T., P.J.N., G.V.W.), University of Oxford, Oxford OX3 7LJ, United Kingdom; Division of Endocrinology (J.B.), Department of Medicine, College of Physicians and Surgeons, Columbia University, New York, New York 10032; Department of General Surgery (H.D.), Martin Luther University, 06097 Halle-Wittenberg, Germany; Faculty of Medicine, Dentistry and Health Sciences (P.R.E.), University of Melbourne, Melbourne, Victoria 3010, Australia; Division of Endocrinology and Metabolism (S.M.), Cedars-Sinai Medical Center, Los Angeles, California 90048; Department of Medical Genetics (A.S.), Shinshu University School of Medicine, 390-8621 Matsumoto, Japan; and Departments of Clinical Physiopathology (F.T.) and Internal Medicine (M.L.B.), University of Florence, 50134 Florence, Italy

Objective: The aim was to provide guidelines for evaluation, treatment, and genetic testing for multiple endocrine neoplasia type 1 (MEN1).

Participants: The group, which comprised 10 experts, including physicians, surgeons, and geneticists from international centers, received no corporate funding or remuneration.

Process: Guidelines were developed by reviews of peer-reviewed publications; a draft was prepared, reviewed, and rigorously revised at several stages; and agreed-upon revisions were incorporated.

Conclusions: MEN1 is an autosomal dominant disorder that is due to mutations in the tumor suppressor gene *MEN1*, which encodes a 610-amino acid protein, menin. Thus, the finding of MEN1 in a patient has important implications for family members because first-degree relatives have a 50% risk of developing the disease and can often be identified by *MEN1* mutational analysis. MEN1 is characterized by the occurrence of parathyroid, pancreatic islet, and anterior pituitary tumors. Some patients may also develop carcinoid tumors, adrenocortical tumors, meningiomas, facial angiofibromas, collagenomas, and lipomas. Patients with MEN1 have a decreased life expectancy, and the outcomes of current treatments, which are generally similar to those for the respective tumors occurring in non-MEN1 patients, are not as successful because of multiple tumors, which may be larger, more aggressive, and resistant to treatment, and the concurrence of metastases. The prognosis for MEN1 patients might be improved by presymptomatic tumor detection and undertaking treatment specific for MEN1 tumors. Thus, it is recommended that MEN1 patients and their families should be cared for by multidisciplinary teams comprising relevant specialists with experience in the diagnosis and treatment of patients with endocrine tumors. (*J Clin Endocrinol Metab* 97: 2990–3011, 2012)

Summary of Recommendations

General recommendations

Patients with multiple endocrine neoplasia (MEN) type 1 (MEN1) and their families should be managed by a multidisciplinary team (MDT) consisting of relevant specialists with experience in the management of endocrine tumors (2|⊕⊕○○).

MDT representation should include specialist physicians (*e.g.* endocrinologist, gastroenterologist, and oncologist) in the management of neuroendocrine tumors (NET), endocrine surgeons, histopathologists (with expertise in NET), radiologists (including those with expertise in nuclear medicine), and clinical geneticists (2|⊕⊕○○).

Genetic testing

MEN1 germline mutation testing should be offered to index patients with MEN1 and their first-degree relatives. This includes relatives who are either asymptomatic or who have clinical manifestations of MEN1 (1|⊕⊕⊕○).

MEN1 germline mutation testing of asymptomatic relatives should be offered at the earliest opportunity because MEN1 manifestations may occur by the age of 5 yr (2|⊕⊕○○).

MEN1 germline mutation testing may be recommended in individuals with an atypical MEN1 phenotype (*e.g.* multigland hyperparathyroidism) (2|⊕⊕○○).

All individuals offered *MEN1* mutation testing should be provided with genetic counseling before testing (1|⊕⊕⊕○).

MEN1 germline mutation testing should be undertaken by a clinical genetics laboratory accredited in mutation analysis of the *MEN1* gene (1|⊕⊕⊕○). If a coding region *MEN1* mutation is not identified, then testing for partial or whole-gene deletion, or haplotype analysis of the *MEN1* locus, or analysis of other genes should be considered (1|⊕⊕⊕○).

Relatives of a patient with a known *MEN1* mutation should be offered *MEN1* germline mutation analysis before biochemical and radiological screening tests for the detection of MEN1 tumors, so as to avoid the burden of undergoing multiple tests involving different modalities and to reduce financial costs (1|⊕⊕⊕○).

Individuals who are found to have a *MEN1* germline mutation should be screened regularly (*e.g.* on an annual basis) for development of MEN1-associated tumors (1|⊕⊕⊕○).

Screening for tumors

Individuals identified as having a high risk of developing MEN1-associated tumors [*e.g.* index cases (*i.e.* MEN1 patients) and their relatives who have been identified as

having a *MEN1* mutation] should be offered a program of combined clinical, biochemical, and radiological screening as detailed below. The nature and timing of screening will depend on local resources, clinical judgment, and patient preferences (2|⊕⊕○○).

Parathyroid tumors

Diagnosis

Screening for primary hyperparathyroidism should include annual assessment of plasma calcium and PTH concentrations (1|⊕⊕⊕○).

Treatment

Surgery performed by an experienced endocrine surgeon is the treatment of choice, although the optimum timing has not been defined. Conventional open bilateral exploration with subtotal parathyroidectomy (at least 3.5 glands) or total parathyroidectomy is recommended (1|⊕⊕⊕○). Concurrent transcervical thymectomy is also suggested at the time of surgery (2|⊕⊕○○). Total parathyroidectomy with autotransplantation may be considered (2|⊕⊕○○). Minimally invasive parathyroidectomy is usually not recommended because multiple glands are typically affected (1|⊕⊕⊕○).

Pancreatic NET

Diagnosis

Screening for gastropancreatic NET should include, as a minimum, an annual plasma biochemical evaluation of a fasting gastrointestinal tract hormone profile that includes measurement of gastrin, glucagon, vasointestinal polypeptide, pancreatic polypeptide, chromogranin A, and insulin with an associated fasting glucose level (2|⊕⊕○○).

A consensus for optimum radiological screening has not been established and will depend on local resources, clinical judgment, and patient preferences. A suggested minimum imaging protocol includes annual pancreatic and duodenal visualization with magnetic resonance imaging (MRI), computed tomography (CT), or endoscopic ultrasound (2|⊕⊕○○).

Treatment

The main aim is to maintain patients disease- and symptom-free for as long as possible and to maintain a good quality of life (1|⊕⊕⊕○).

The aim of treatment for individuals with symptomatic functioning pancreatic NET including insulinoma is to achieve cure, if possible, by surgery (1|⊕⊕⊕○).

The extent of disease should be evaluated fully before planning specific therapy (1|⊕⊕⊕○).

The optimal therapy of gastrinoma remains controversial. Surgery for a nonmetastasizing gastrinoma arising within the pancreas may be curative and should be considered, as long as it is performed by an experienced endocrine surgeon (2|⊕⊕○○). However, most MEN1 patients will have multiple small submucosal duodenal gastrinomas, and the management of such tumors remains controversial. We suggest medical management using proton-pump inhibitors for the majority of patients (2|⊕⊕○○). However, in experienced surgical centers local excision of these tumors with lymph node dissection, duodenectomy, or less commonly duodenopancreatectomy may also be considered together with patient preferences, because such approaches may improve the cure rate (2|⊕⊕○○). Although Whipple pancreaticoduodenectomy provides the greatest likelihood of cure for gastrinoma in MEN1 patients, we do not suggest it for the majority of patients because it is associated with an increased operative mortality and long-term morbidity and because lesser operations in these patients are associated with excellent long-term survival (2|⊕⊕○○).

Medical therapies include proton-pump inhibitors and somatostatin analogs to suppress hyperacidity (1|⊕⊕⊕⊕). Periodic gastroscopic surveillance is indicated in those with hypergastrinemia for the identification of peptic ulcer disease and gastric carcinoid (2|⊕⊕○○).

The role of surgery for nonfunctioning pancreatic tumors is controversial. We suggest considering surgery for tumors that are more than 1 cm in size and/or demonstrate significant growth over 6–12 months (2|⊕⊕○○).

A histopathologist with expertise in NET should review all tumor tissues. Tumors should be classified according to the World Health Organization 2010 classification, Union for International Cancer Control TNM (7th edition), and the European Neuroendocrine Tumor Society site-specific T-staging system (1|⊕⊕⊕⊕).

Treatment of nonresectable tumor mass includes somatostatin analogs, biotherapy, targeted radionuclide therapy, locoregional treatments, and chemotherapy (1|⊕⊕⊕⊕).

Chemotherapy may be used for inoperable or metastatic pancreatic NET (1|⊕⊕⊕⊕). Sunitinib and everolimus may be considered for patients with advanced (inoperable or metastatic) progressive well-differentiated pancreatic NET (1|⊕⊕⊕⊕).

Pituitary tumors

Diagnosis

Biochemical screening for pituitary tumors, which will depend on clinical judgment and local resources, could include an annual assessment of plasma prolactin and IGF-I levels (2|⊕⊕⊕⊕), as well as MRI of the pituitary every 3–5 yr (2|⊕⊕○○). In patients with abnormal results,

hypothalamic pituitary testing should be undertaken to characterize further the nature of the pituitary lesion and its effects on the secretion of other pituitary hormones (1|⊕⊕⊕⊕).

Treatment

Treatment of MEN1-associated pituitary tumors is similar to that for non-MEN1 pituitary tumors and consists of appropriate medical therapy (*e.g.* dopamine agonists for prolactinoma; octreotide or lanreotide for somatotrophinomas) or selective transsphenoidal surgical hypophysectomy, with radiotherapy reserved for residual unresectable tumor tissue (1|⊕⊕⊕⊕).

Thymic, bronchopulmonary, and gastric NET

Diagnosis

Biochemical evaluation with urinary 5-hydroxyindoleacetic acid and chromogranin A is not helpful (1|⊕⊕⊕⊕).

CT or MRI of the chest every 1–2 yr is recommended for detection of thymic and bronchopulmonary carcinoid tumors (2|⊕○○○).

Gastroscopic examination (with biopsy) every 3 yr in those with hypergastrinemia for detection of peptic ulcer disease and gastric carcinoid type II is recommended (2|⊕⊕○○). Endoscopic ultrasound and somatostatin receptor scintigraphy may aid the diagnosis (1|⊕⊕⊕⊕).

Treatment

Curative surgery, where possible, is the treatment of choice for thymic and bronchial carcinoid tumors (1|⊕⊕⊕⊕).

Where disease is advanced and curative surgery is not possible, additional therapies include radiotherapy and chemotherapy (2|⊕○○○).

The optimal treatment of type II gastric carcinoids has not been established. Small (<10 mm) lesions may remain under endoscopic surveillance. Larger tumors require endoscopic resection or local resection with partial or total gastrectomy. Indications for somatostatin analogs in the treatment of type II gastric carcinoids are not defined (2|⊕⊕○○).

Adrenal tumors

Diagnosis

Minimal screening should comprise abdominal imaging by CT or MRI every 3 yr (2|⊕⊕○○). Adrenal lesions should remain under radiological surveillance and should be assessed for malignant features (1|⊕⊕⊕⊕).

Images should be reviewed by a radiologist with expertise in adrenal imaging (1|⊕⊕⊕⊕).

Biochemical evaluation of adrenal lesions should be restricted to those with clinical features or tumors more than 1 cm in size and should focus on assessment for primary hyperaldosteronism and primary hypercortisolemia (1|⊕⊕⊕⊕).

Treatment

Treatment of MEN1-associated adrenal tumors is similar to that for non-MEN1 adrenal tumors. Surgery is indicated for functioning tumors (e.g. primary hyperaldosteronism or hypercortisolism), and nonfunctioning tumors with atypical features, size greater than 4 cm, or significant growth over a 6-month interval (1|⊕⊕⊕⊕).

Method of Development of Clinical Practice Guideline

These guidelines update those published in 2001 (1). The authors, who are a self-assembled group representing international leaders in the field of MEN and/or associated endocrinopathies, undertook a systematic review of the literature to inform its key recommendations. These guidelines therefore represent the views of the authors rather than the guideline process of The Endocrine Society. However, in line with the policy of The Endocrine Society, the strength of recommendation and the assessment of quality of evidence are based on the Grading of Recommendations, Assessment, Development, and Evaluation (GRADE) system (2, 3). In addition, we have adopted consistent language in the description of both the strength of recommendation and the quality of evidence. Strong recommendations use the phrase “we recommend” and the number 1, whereas weak recommendations use the phrase “we suggest” and the number 2. Similarly, *cross-filled circles* indicate the quality of evidence, such that ⊕○○○ denotes very low quality evidence; ⊕⊕○○, low quality; ⊕⊕⊕○, moderate quality; and ⊕⊕⊕⊕, high quality.

There is currently a lack of evidence from controlled clinical trials that specifically evaluate methods of diagnosis and screening for the tumors or treatment of MEN1. As such, many of the recommendations in these guidelines are based on the balance of expert opinion from leaders in the field, rather than on the level of evidence which, in the absence of controlled clinical trials that are difficult to undertake for a rare disorder, must be considered weak. Furthermore, these guidelines are not intended to constitute a rigid protocol, but rather are intended to provide a framework on which to base care for MEN1 patients and their families; the appropriate use of these guidelines with caution will help to avoid the undesirable effects of a recommendation, which can include the burden of anxiety and

expense for patients and their families. The authors have confidence that persons who receive care according to the strong recommendations will derive, on average, more benefit than harm. Weak recommendations require more careful consideration of the patient’s circumstances, values, and preferences to determine the best course of action.

Multiple Endocrine Neoplasia

MEN is characterized by the occurrence of tumors involving two or more endocrine glands in a single patient (4, 5). Two major forms of MEN are recognized and referred to as type 1 (MEN1) and type 2 (MEN2), and each form is characterized by development of tumors within specific endocrine glands (Table 1) (4, 6). Thus, combined occurrence of tumors of the parathyroid glands, the pancreatic islet cells, and the anterior pituitary is characteristic of MEN1 (4). MEN2 is characterized by medullary thyroid carcinoma (MTC) in association with pheochromocytoma, and three clinical variants referred to as MEN2A, MEN2B, and MTC-only are recognized (Table 1). MEN1 and MEN2 may be inherited as autosomal-dominant syndromes or they may occur sporadically, that is, without a family history. However, this distinction between sporadic and familial cases may sometimes be difficult because in some sporadic cases, a family history may be absent because the parent with the disease may have died before symptoms developed. Also, some patients may be unrecognized because of the lack of symptoms. These guidelines review the clinical features of MEN1 and their diagnosis, treatments for MEN1-associated tumors, and the genetic advances used to select patients for screening programs for tumor detection.

MEN type 1

Epidemiology

The incidence of MEN1 has been estimated from random postmortem studies to be 0.25%, and to be 1–18% in patients with primary hyperparathyroidism, 16–38% in patients with gastrinomas, and less than 3% in patients with pituitary tumors (4, 5). The disorder affects all age groups, with a reported age range of 5 to 81 yr (1, 4, 7). MEN1 is inherited as an autosomal dominant disorder with a high degree of penetrance such that clinical and biochemical manifestations of the disorder will have developed in 80% and greater than 98% of MEN1 patients, respectively, by the fifth decade (1, 4, 7).

Clinical findings

The clinical manifestations of MEN1 are related to the sites of the tumors and their products of secretion (Table

TABLE 1. MEN syndromes and their characteristic tumors and associated genetic abnormalities

Type (chromosome location)	Tumors (estimated penetrance)	Gene, most frequently mutated codons
MEN1 (11q13)	Parathyroid adenoma (90%) Enteropancreatic tumor (30–70%): gastrinoma (40%), insulinoma (10%), nonfunctioning and PPoma (20–55%), glucagonoma (<1%), VIPoma (<1%) Pituitary adenoma (30–40%): prolactinoma (20%), somatotrophinoma (10%), corticotrophinoma (<5%), nonfunctioning (<5%) Associated tumors: adrenal cortical tumor (40%), pheochromocytoma (<1%), bronchopulmonary NET (2%), thymic NET (2%), gastric NET (10%), lipomas (30%), angiofibromas (85%), collagenomas (70%), meningiomas (8%)	<i>MEN1</i> 83/84, 4-bp del (≈4%) 119, 3-bp del (≈3%) 209–211, 4-bp del (≈8%) 418, 3-bp del (≈4%) 514–516, del or ins (≈7%) Intron 4 ss, (≈10%)
MEN2 (10 cen-10q11.2)		
MEN2A	MTC (90%) Pheochromocytoma (50%) Parathyroid adenoma (20–30%)	<i>RET</i> 634, missense e.g. Cys→Arg (~85%)
MTC only	MTC (100%)	<i>RET</i> 618, missense (>50%)
MEN2B (also known as MEN3)	MTC (>90%) Pheochromocytoma (40–50%) Associated abnormalities (40–50%) Mucosal neuromas Marfanoid habitus Medullated corneal nerve fibers Megacolon	<i>RET</i> 918, Met→Thr (>95%)
MEN4 (12p13)	Parathyroid adenoma ^a Pituitary adenoma ^a Reproduction organ tumors (e.g. testicular cancer, neuroendocrine cervical carcinoma) ^a ?Adrenal + renal tumors ^a	<i>CDKN1B</i> No common mutations identified to date

Autosomal-dominant inheritance of the MEN syndromes has been established. del, Deletion; ins, insertion; PPoma, pancreatic polypeptide-secreting tumor. [Adapted from R. V. Thakker: Multiple endocrine neoplasia—syndromes of the twentieth century. *J Clin Endocrinol Metab* 83: 2617–2620, 1998 (6), with permission. © The Endocrine Society.]

^a Insufficient numbers reported to provide prevalence information.

1). Parathyroid tumors, resulting in primary hyperparathyroidism, are the most common feature of MEN1 and occur in approximately 95% of MEN1 patients (1, 4, 5). Pancreatic islet tumors, also referred to as pancreatic NET, consist of gastrinomas, insulinomas, glucagonomas, vasoactive intestinal polypeptidomas (VIPomas), and nonfunctioning pancreatic NET, and these occur in approximately 40–70% of MEN1 patients (1, 8–10); and anterior pituitary tumors, consisting of prolactinomas, somatotrophinomas, corticotrophinomas, and nonfunctioning adenomas, occur in approximately 30–40% of patients (1, 11–13). In addition, some MEN1 patients may also develop adrenocortical tumors, lipomas, carcinoid tumors, facial angiofibromas, collagenomas, and meningiomas (Table 1) (1, 14). Combinations of these affected glands and their respective pathological features (for example, hyperplasia or single or multiple adenomas of the parathyroid glands) may differ in members of the same

family and even between identical twins (15). MEN1 is inherited as an autosomal-dominant disorder in such families, but a nonfamilial (*i.e.* sporadic) form may have developed in 8 to 14% of patients with MEN1, and molecular genetic studies have confirmed the occurrence of *de novo* mutations of the *MEN1* gene in approximately 10% of all patients with MEN1 (4, 16). In the absence of treatment, endocrine tumors are associated with an earlier mortality in patients with MEN1. Thus, untreated patients with MEN1 have a decreased life expectancy with a 50% probability of death by the age of 50 yr, and the cause of death in 50–70% of patients with MEN1 is usually a malignant tumor process or sequelae of the disease (17–20). Although the prognosis of patients with MEN1 improved considerably after the introduction of acid-suppressive therapies for the treatment of gastrinoma and the Zollinger-Ellison syndrome (ZES), results of a multicenter study from France and Belgium have suggested that ap-

proximately 70% of individuals with MEN1 currently die of causes directly related to MEN1 (17). In particular, malignant pancreatic NET and thymic carcinoid tumors were associated with a marked increase in risk of death (hazard ratio, >3 ; $P < 0.005$) (17). These studies highlight the shift in MEN1-associated mortality that has occurred from gastrinoma associated with ZES to other MEN1-associated malignant tumors (17).

Diagnosis

A diagnosis of MEN1 may be established in an individual by one of three criteria (Fig. 1) (1, 16, 21): on the basis of the occurrence of two or more primary MEN1-associated endocrine tumors (*i.e.* parathyroid adenoma, enteropancreatic tumor, and pituitary adenoma) (Fig. 1); the occurrence of one of the MEN1-associated tumors in a first-degree relative of a patient with a clinical diagnosis of MEN; and identification of a germline *MEN1* mutation in an individual, who may be asymptomatic and has not yet developed serum biochemical or radiological abnormalities indicative of tumor development (Fig. 1).

Treatment

The treatment for each type of MEN1-associated endocrine tumor is generally similar to that for the respective tumors occurring in non-MEN1 patients. However, the treatment outcomes of MEN1-associated tumors are not as successful as those in non-MEN1 patients, for several reasons. First, MEN1-associated tumors, with the exception of pituitary NET, are usually multiple, thereby making it difficult to achieve a successful surgical cure. For example, MEN1 patients often develop multiple submucosal duodenal gastrinomas, thereby reducing surgical cure rates compared with similar sporadic solitary tumors, such that only approximately 15% of MEN1 patients, compared with approximately 45% of non-MEN1 patients, are free of disease immediately after surgery, and at

5 yr this decreased to approximately 5% in MEN1 patients, compared with approximately 40% in non-MEN1 patients (1, 22–25). MEN1 patients also develop multiple parathyroid tumors, and subtotal parathyroidectomy has resulted in persistent or recurrent hypercalcemia within 10 yr in 20–60% of MEN1 patients, as opposed to approximately 4% in non-MEN1 patients (1, 26, 27). Secondly, occult metastatic disease is more prevalent in MEN1 patients with NET than in patients with sporadic endocrine tumors. For example, metastases are present in up to 50% of patients with MEN1-associated insulinomas, whereas less than 10% of non-MEN1 insulinomas metastasize (28). Thirdly, MEN1-associated tumors may be larger, more aggressive, and more resistant to treatment. For example, approximately 85% of anterior pituitary tumors in MEN1 patients, as opposed to 64% in non-MEN1 patients, are macroadenomas at the time of diagnosis; approximately 30% of anterior pituitary tumors in MEN1 patients have invaded surrounding tissue (Hardy classification grades III and IV), compared with 10% in non-MEN1 patients; and more than 45% of anterior pituitary NET in MEN1 patients had persistent hormonal oversecretion after appropriate medical, surgical, and radiotherapy treatment, compared with between 10 and 40% in non-MEN1 patients (11, 12, 29).

Parathyroid tumors

Clinical manifestations and diagnosis

Primary hyperparathyroidism is the most common feature of MEN1 and occurs in approximately 90% of all patients with MEN1 (Table 1) (1, 4). Patients may have asymptomatic hypercalcemia, nephrolithiasis, osteitis fibrosa cystica, vague symptoms associated with hypercalcemia (*e.g.* polyuria, polydipsia, constipation, or malaise), or occasionally peptic ulcers. Biochemical investigations reveal hypercalcemia, usually in association with increased circulating PTH concentrations. The hypercalcemia is usually mild, and severe hypercalcemia resulting in crisis or parathyroid cancers is rare. Additional differences in the primary hyperparathyroidism associated with MEN1, compared with features of the disorder in those patients without MEN1, include earlier age at onset (20 to 25 yr *vs.* 55 yr), greater reduction in bone mineral density (30), and an equal male/female ratio (1:1 *vs.* 1:3) (1, 4, 7). Preoperative imaging (*e.g.* neck ultrasound with Tc99m-sestamibi parathyroid scintigraphy) is of limited benefit because all parathyroid glands may be affected, and neck exploration is required irrespective of preoperative localization studies.

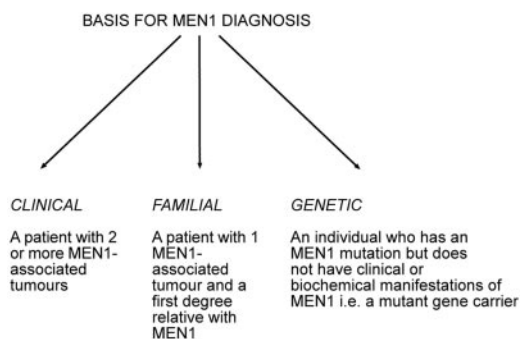


FIG. 1. Basis for a diagnosis of MEN1 in individuals. A diagnosis of MEN1 based on clinical and familial criteria may be confounded by the occurrence of phenocopies. [Reproduced from J. J. Turner *et al.*: Diagnostic challenges due to phenocopies: lessons from multiple endocrine neoplasia type 1 (MEN1). *Hum Mutat* 31:E1089–E1101, 2010 (90), with permission. © Wiley Periodicals Inc.]

Treatment

Surgical removal of the abnormally overactive parathyroid glands in patients with MEN1 is the definitive treatment, but it is controversial whether to perform subtotal (3.5 glands) or total parathyroidectomy and whether surgery should be performed at an early or late stage of the disease. Open bilateral neck exploration is recommended, as opposed to minimally invasive parathyroidectomy, because all four parathyroid glands are usually affected with multiple adenomas or hyperplasia, although this histological distinction may be difficult; parathyroid carcinoma is rarely found in patients with MEN1, and to date only three patients with germline *MEN1* mutations have been reported to have parathyroid carcinoma (31, 32). Subtotal parathyroidectomy (*i.e.* removal of ≤ 3.5 glands) has resulted in persistent or recurrent hypercalcemia within 10 to 12 yr after surgery in 40 to 60% of patients, and in hypocalcemia requiring long-term therapy with vitamin D or its active metabolite calcitriol in 10 to 30% of patients with MEN1 (26, 27, 33, 34). These recurrence rates are markedly higher than those observed after parathyroidectomy in patients who do not have MEN1, in whom recurrent hypercalcemia occurs in 4 to 16% and hypocalcemia in 1 to 8% of patients. For total parathyroidectomy with autotransplantation, both fresh and cryopreserved parathyroid tissue has been used. However, this procedure is dependent on the vitality of cryopreserved cells, which decreases with the time interval from cryopreservation to autotransplantation (35). An alternate approach is intraoperative monitoring of PTH by rapid assay during surgery to determine successful removal of hyperfunctioning parathyroid tissue and to help with the decision to implant parathyroid tissue in the forearm (35). The presence of functioning autotransplanted parathyroid tissue leads to recurrent hypercalcemia in more than 50% of patients with MEN1, and surgical removal of the transplanted grafts is not always successful. To improve the outcome of parathyroid autotransplantation, one study has reported that the use of less tissue (*e.g.* approximately 10 fresh parathyroid pieces 1 mm³ in size) helps to reduce both the recurrence of hypercalcemia and the hypoparathyroidism rates (35). Autotransplantation of parathyroid tissue to the forearm may be beneficial over subtotal parathyroidectomy because it avoids the necessity for vitamin D medication for the patient. If hypercalcemia recurs, the transplanted parathyroid tissue can be removed under local anesthesia, and reoperation of the neck under general anesthesia can be avoided (35). Subtotal parathyroidectomy is suggested as the initial treatment of primary hyperparathyroidism in MEN1, but total parathyroidectomy with autotransplantation may also be considered in some cases. Total parathyroidectomy may be reserved for those with

extensive disease either at first or at repeat surgery. Persistent hypocalcemia is treated with oral calcitriol (1,25-dihydroxyvitamin D), although management of hypoparathyroidism can be challenging in some patients, even with the use of vitamin D and calcium replacement. One recommendation is that parathyroidectomy be reserved for symptomatic hypercalcemic patients with MEN1 and that asymptomatic hypercalcemic patients with MEN1 do not undergo parathyroid surgery but have regular assessment for symptom onset and complications, at which time subtotal parathyroidectomy with transcervical thymectomy should be undertaken (34, 36). However, the timing of surgery requires careful consideration, and factors such as surgical experience, availability of facilities for long-term regular serum calcium monitoring, accessibility of calcitriol (or vitamin D analogs), and patient preference should be taken into account. Calcimimetics (*e.g.* cinacalcet) that act via the calcium-sensing receptor have been used to treat primary hyperparathyroidism in some patients in whom surgery had either failed or was contraindicated (37).

Pancreatic islet cell tumors (NET)

The incidence of pancreatic NET in patients with MEN1 varies from 30 to 80% in different series (1, 4, 8, 9, 38, 39). Many of these tumors (Table 1) secrete excessive amounts of hormone [for example, gastrin, insulin, or vasoactive intestinal polypeptide (VIP)] and are associated with distinct clinical syndromes, although some (for example, those secreting pancreatic polypeptide) may not be associated with clinical manifestations or may be nonsecretory (*i.e.* nonfunctioning). These pancreatic NET have an earlier age of onset in patients with MEN1 than in patients without MEN1 (1, 7, 40, 41). Given that MEN1-associated pancreatic NET are frequently multiple and their behavior uncertain, their accurate diagnosis and management presents significant challenges. For example, it cannot be assumed that tumor visualization on imaging studies correlates with the site of hormone excess in functioning tumor syndromes (*e.g.* gastrinoma, insulinoma).

Gastrinoma

Clinical manifestations and diagnosis

Gastrin-secreting tumors (gastrinomas) are associated with marked gastric acid production and recurrent peptic ulcerations, a combination also referred to as the ZES. Gastrinomas represent more than 50% of all neuroendocrine duodenopancreatic tumors in patients with MEN1 (Table 1), and approximately 20% of patients with gastrinomas will have MEN1 (1, 23, 38, 42, 43). Gastrinomas frequently appear as small (<5 mm in diameter), multiple nodular lesions arising deep in the mucosa. Gastrinomas

usually will grow slowly but can frequently metastasize to the peripancreatic lymph nodes and rarely to the liver. Gastrinomas are rarely found in the pancreas, where they may be difficult to distinguish from concomitant nonfunctioning neuroendocrine pancreatic tumors, and in this eventuality selective arterial secretagogue injection test (SASI test) may help in localizing the gastrin-secreting tumor (23–25, 42). Gastrinomas occur more often in patients with MEN1 who are older than 30 yr, and recurrent severe multiple peptic ulcers, which may perforate, contribute to the high morbidity. Patients with ZES may also suffer from diarrhea and steatorrhea. The diagnosis is established by demonstration of an increased fasting serum gastrin concentration in association with increased basal gastric acid secretion (gastric pH, <2). Occasionally, iv provocative tests with either secretin (2 U/kg) or calcium infusion (4 mg Ca²⁺/kg·h for 3 h) are required to distinguish patients with ZES from other patients with hypergastrinemia, such as those with antral G-cell hyperplasia. However, in patients with MEN1, ZES does not appear to develop in the absence of primary hyperparathyroidism, and hypergastrinemia has also been reported to be associated with hypercalcemia (43). Thus, the diagnosis of ZES may be difficult in some patients with MEN1. Moreover, successful treatment of primary hyperparathyroidism with restoration of normocalcemia will significantly ameliorate clinical symptoms and biochemical abnormalities in as many as 20% of MEN1 patients with ZES. Ultrasonography, endoscopic ultrasonography, CT, MRI, selective abdominal angiography, or somatostatin-receptor scintigraphy are helpful in localizing the tumor (24, 44, 45). The combined use of intraarterial calcium injections with hepatic venous gastrin sampling has been shown to regionalize the gastrinomas (24, 44).

Treatment

Medical treatment of patients with MEN1 and ZES is directed toward reducing basal acid output to less than 10 mmol/liter, and such reduced acid output may be achieved by parietal cell H⁺-K⁺-adenosine triphosphatase inhibitors (*e.g.* omeprazole or lansoprazole), which have proved efficacious and have become the drugs of choice for gastrinomas (1). Some patients may also require additional treatment with the histamine H₂ receptor antagonists, cimetidine or ranitidine. The role of surgery in treating patients with MEN1-associated gastrinomas is controversial (23, 24, 42, 46). The goal of surgery should be to reduce the risk of distant metastatic disease and improve survival, and the prognosis of MEN1 patients with gastrinoma has been reported to be associated with tumor size and the presence of hepatic metastases (47). Thus, the risk of hepatic metastases has been reported to increase with tumor

size, such that 25–40% of patients with pancreatic NET larger than 4 cm develop hepatic metastases, and 50–70% of MEN1 patients with tumors 2–3 cm in size have lymph node metastases (22, 47). Survival in patients with MEN1 with gastrinomas less than 2.5 cm in size has been reported to be 100% at 15 yr, and 52% at 15 yr if metastatic disease is present although the presence of lymph node metastases does not appear to adversely affect survival (22, 47–49). The ideal treatment for a nonmetastatic gastrinoma situated within the pancreas is surgical excision, and we recommend surgery for pancreatic gastrinomas because the disease-related survival in patients with tumors that are more than 2 cm has been reported to be improved after surgery (23). However, in most patients with MEN1, gastrinomas are multiple and occur within the duodenum, and some reports indicate that surgical cure may be difficult. For example, the results of one study revealed that only 16% of patients with MEN1 were free of disease immediately after surgery, and at 5 yr, this number had decreased to 6%; the respective outcomes in patients without MEN1 were better, at 45 and 40% (22). However, other recent studies have reported that up to 77% of hypergastrinemic MEN1 patients were eugastrinemic, with a negative secretin provocation test at 6-month follow-up after duodenectomy, pancreatoduodenectomy, or total pancreatectomy (24, 25). Further studies are required to identify whether such surgery achieves long-term remission and an improvement in survival (24). Although Whipple pancreaticoduodenectomy has been reported to achieve a greater than 65% cure rate, it is associated with a higher operative mortality and long-term complications, which include weight loss, diabetes mellitus, and malabsorption. Most centers, therefore, do not offer Whipple resection for the majority of MEN1 patients, particularly because the lesser operations (or no surgery) are associated with excellent survival, *e.g.* 52 and 100% at 15 yr in patients with and without metastases, respectively (47, 49). Indeed, most centers undertake a nonsurgical management for gastrinomas in MEN1 unless pancreatic gastrinomas more than 2 cm in size are identified, in which case surgery is recommended. However, surgical resection of duodenal MEN1-associated gastrinomas based on appropriate preoperative and intraoperative (*e.g.* transillumination of the duodenum) imaging and regionalization may be considered in specialized centers. Due to increased morbidity and potential mortality after extensive resections, we recommend that the surgical procedure be individualized according to preoperative findings, patient history (*e.g.* preexisting insulin-dependent diabetes), and patient preference. Treatment of disseminated gastrinomas is difficult, and chemotherapy with streptozotocin and 5-fluorouracil; hormonal therapy with somatosta-

tin analogs, octreotide or lanreotide; hepatic artery embolization; administration of human leukocyte interferon; and removal of all resectable tumor have been occasionally successful (4).

Insulinoma

Clinical manifestations and diagnosis

Insulinomas, β -islet cell tumors that secrete insulin, represent 10 to 30% of all pancreatic tumors in patients with MEN1 (Table 1). Insulinomas are usually a single lesion more than 5 mm in diameter, but they can be associated with other neuroendocrine pancreatic tumors at the time of diagnosis in 10% of patients with MEN1, and the two tumors may arise at different times. Insulinomas occur more often in patients with MEN1 who are younger than 40 yr, and many of them arise in individuals younger than 20 yr, whereas in patients without MEN1, insulinomas generally occur in those older than 40 yr (1, 4, 7, 50, 51). Insulinomas may be the first manifestation of MEN1 in 10% of patients, and approximately 4% of patients with insulinomas will have MEN1 (1, 4). Patients with an insulinoma present with hypoglycemic symptoms that develop after a fast or exertion and improve after glucose intake. The most reliable test is a supervised 72-h fast, during which increased plasma insulin concentration in association with hypoglycemia is demonstrated. Elevated circulating C-peptide and proinsulin concentrations may establish the diagnosis (1, 4). It also is important to exclude the presence of oral hypoglycemic agents (*e.g.* sulfonylureas) in plasma and urine samples obtained during hypoglycemia evaluation. Preoperative localization with endoscopic ultrasonography, MRI, CT scanning, or celiac axis angiography, selective intraarterial stimulation with hepatic venous sampling, and intraoperative direct pancreatic ultrasonography is likely to improve the success rate of surgery (1, 4, 45).

Treatment

Medical treatment, which consists of frequent carbohydrate meals and diazoxide or octreotide, is not always successful, and surgery is the optimal treatment (1, 4). Surgical treatment, which ranges from enucleation of a single tumor to distal pancreatectomy or partial pancreatectomy, or excision of all the macroscopic pancreatic tumors with enucleation of nodules in the remaining pancreas has been curative in many patients. In addition, monitoring the insulin/glucose ratio during surgery has been reported to be of value in assessing successful removal of the insulinoma (52). Chemotherapy consisting of streptozotocin, 5-fluorouracil, and doxorubicin or hepatic artery embolization has been used for metastatic disease (1, 4).

Glucagonoma

Clinical manifestations and diagnosis

Glucagonomas, glucagon-secreting pancreatic tumors, occur in fewer than 3% of patients with MEN1, although some nonfunctioning pancreatic NET may immunostain for glucagon (Table 1) (1, 4, 39, 52). The characteristic clinical manifestations of a skin rash (necrolytic migratory erythema), weight loss, anemia, and stomatitis may be absent, and the presence of the tumor may have been detected in an asymptomatic patient with MEN1 undergoing pancreatic imaging or detected by glucose intolerance and hyperglucagonemia.

Treatment

The tail of the pancreas is the most frequent site for glucagonomas, and surgical removal is the treatment of choice. However, treatment may be difficult because approximately 50 to 80% of patients have metastases at the time of diagnosis (28). Medical treatment with somatostatin analogs (*e.g.* octreotide or lanreotide), or chemotherapy with streptozotocin, and 5-fluorouracil, or dimethyltriazeno-imidazole carboxamide has been successful in some patients, and hepatic artery embolization has been used to treat metastatic disease (1, 4).

VIP-secreting tumors (VIPomas)

Clinical manifestations and diagnosis

VIPomas have been reported in only a few patients with MEN1 (Table 1) who develop watery diarrhea, hypokalemia, and achlorhydria (WDHA). This clinical syndrome has been referred to as the Verner-Morrison syndrome, the WDHA syndrome, or the VIPoma syndrome (28). The diagnosis is established by excluding laxative and diuretic abuse, by confirming a stool volume in excess of 0.5 to 1.0 liters/d during a fast, and by documenting a markedly increased plasma VIP concentration.

Treatment

Surgical management of VIPomas, which are mostly located in the tail of the pancreas, has been curative (1, 4). However, in patients with unresectable tumor, treatment with somatostatin analogs such as octreotide and lanreotide, streptozotocin with 5-fluorouracil, corticosteroids, indomethacin, metoclopramide, and lithium carbonate has proved beneficial, and hepatic artery embolization has been useful for the treatment of metastases (1, 4).

Nonfunctioning pancreatic NET

Clinical manifestations and diagnosis

Nonfunctioning pancreatic tumors are not associated with a clinical syndrome. These include those associated

with minor elevation of pancreatic hormones (*e.g.* pancreatic polypeptide, glucagon) but no clinical features. Nonfunctioning pancreatic NET may represent a heterogeneous group with different distinct subtypes, although currently they are classified as a single group. The increasing sensitivity of radiological screening methods has resulted in an increased identification of nonfunctioning pancreatic NET (40, 45). For example, an endoscopic ultrasound study identified nonfunctioning pancreatic NET in approximately 55% of patients with MEN1 (Table 1) (8). Such nonfunctioning pancreatic NET have been reported to occur in asymptomatic patients who are less than 15 yr of age (40).

Identification of nonfunctioning pancreatic NET is of particular clinical importance for the following reasons. First, malignant pancreatic NET are now reported to be the commonest cause of death in individuals with MEN1 (17–19, 41). Second, nonfunctioning tumors are increasingly recognized, with recent studies indicating that these tumors are the most common enteropancreatic NET associated with MEN1 and, furthermore, are associated with a worse prognosis than other functioning tumors including insulinoma and gastrinoma (8, 41). Finally, the absence of both a clinical syndrome and specific biochemical abnormalities may result in delayed diagnosis of nonfunctioning pancreatic NET in the absence of radiological assessment. Thus, radiological screening for enteropancreatic NET in MEN1 should begin by the age of 10 yr (Table 2). The optimum screening method and its timing interval remain to be established (8, 53). For example, comparison of imaging modalities for detection of pancreatic NET has demonstrated that endoscopic ultrasound is likely to represent the most sensitive method of detecting small pancreatic tumors, whereas somatostatin receptor scintigraphy is the most reliable method for detect-

ing metastatic disease (8, 53). However, the ability to undertake regular endoscopic ultrasound for screening will depend on the availability of local resources. Furthermore, the clinical significance of small pancreatic tumors (*e.g.* <1 cm) in asymptomatic individuals is yet to be fully evaluated.

Treatment

Management of asymptomatic nonfunctioning pancreatic NET is controversial. The goal of treatment is to reduce morbidity and mortality associated with metastatic disease, while preserving pancreatic tissue and avoiding complications associated with surgery. Recommendations to date have been based on tumor size after the observation of an increased rate of metastases in those patients with larger tumors (40, 41, 54, 55). For example, one study reported the presence of synchronous metastases in 43% of patients with nonfunctioning NET of more than 3 cm, 18% of patients with NET 2.1–3.0 cm, and only 4% of patients with tumors of less than 1 cm (41). However, other studies have not confirmed this association (56, 57), and a consensus for the indications for surgery has not been established. Pancreatoduodenal surgery may be successful in tumor excision in 80% of patients, but some patients develop complications that include diabetes mellitus, frequent steatorrhea, early and late dumping syndromes, and other gastrointestinal symptoms (39, 46). We suggest considering surgical resection for nonfunctioning pancreatic NET that are more than 1 cm in size, although other centers recommend surgery only if the tumor is more than 2 cm (54); for tumors less than 1 cm in size, we suggest surgical resection for those that have significant growth, such as a doubling of tumor size, over a 3- to 6-month interval and exceed 1 cm in size. However, in view of the potential morbidity of surgery, this ap-

TABLE 2. Suggested biochemical and radiological screening in individuals at high risk of developing MEN1

Tumor	Age to begin (yr)	Biochemical test (plasma or serum) annually	Imaging test (time interval)
Parathyroid	8	Calcium, PTH	None
Pancreatic NET			
Gastrinoma	20	Gastrin (\pm gastric pH)	None
Insulinoma	5	Fasting glucose, insulin	None
Other pancreatic NET	<10	Chromogranin-A; pancreatic polypeptide, glucagon, VIP	MRI, CT, or EUS (annually)
Anterior pituitary	5	Prolactin, IGF-I	MRI (every 3 yr)
Adrenal	<10	None unless symptoms or signs of functioning tumor and/or tumor >1 cm are identified on imaging	MRI or CT (annually with pancreatic imaging)
Thymic and bronchial carcinoid	15	None	CT or MRI (every 1–2 yr)

EUS, Endoscopic ultrasound. [Adapted from P. J. Newey and R. V. Thakker: Role of multiple endocrine neoplasia type 1 mutational analysis in clinical practice. *Endocr Pract* 17(Suppl 3):8–17, 2011 (21), with permission. © American Association of Clinical Endocrinologists. And from R. V. Thakker: Multiple endocrine neoplasia type 1 (MEN1). *Translational Endocrinology and Metabolism*, Vol 2. (edited by R. P. Robertson and R. V. Thakker), The Endocrine Society, Chevy Chase, MD, 2011, pp 13–44 (5), with permission.]

proach requires an informed patient choice. In addition, when considering these recommendations, it is important to consider that occult metastatic disease (*i.e.* tumors not detected by imaging investigations) may be present in a substantial proportion of these patients at the time of initial presentation, and that after surgery further tumors are likely to recur in remnant pancreatic tissue (39, 58).

Inhibitors of tyrosine kinase receptors (TKR) and of the mammalian target of rapamycin (mTOR) signaling pathway have been reported to be effective in treating pancreatic NET (59, 60). Pancreatic NET may express TKR, vascular endothelial growth factor receptor, and platelet-derived growth factor receptors; some tumors may exhibit IGF-mediated autocrine activation of the mTOR signaling pathway, a serine-threonine kinase that stimulates cell growth proliferation and angiogenesis. Treatment of patients with advanced, well-differentiated pancreatic NET with sunitinib malate, which inhibits TKR, led to increased overall survival and a doubling in progression-free survival when compared with patients receiving placebo (11.4 *vs.* 5.5 months; $P < 0.001$). Treatment of patients with advanced, low-grade or intermediate-grade pancreatic NET with everolimus, an mTOR inhibitor, also led to a doubling of median progression-free survival when compared with patients receiving placebo (11.0 *vs.* 4.6 months; $P < 0.001$) (59). These two studies mainly included non-MEN1 patients; for example, in the sunitinib study, which comprised 171 patients, there were only two MEN1 patients, and none were in the treatment arm (60); in the everolimus study, which had 410 patients, details of MEN1 status were not provided. Nevertheless, these two studies represent major advances in treatment of malignant pancreatic NET in non-MEN1 patients, and it seems highly plausible that these results can be extrapolated to MEN1 patients harboring pancreatic NET.

Other pancreatic NET

NET secreting GHRH, or GHRHomas, have been reported in some patients with MEN1, and approximately 33% of patients with GHRHomas will have other MEN1-related tumors (4, 61). GHRHomas may be diagnosed by finding elevated circulating concentrations of GH and GHRH. More than 50% of GHRHomas arise in the lung, 30% arise in the pancreas, and 10% are found in the small intestine. Surgical removal is the treatment of choice for these tumors. Somatostatinomas, which secrete somatostatin that inhibits GH secretion, result in hyperglycemia, cholelithiasis, low acid output, steatorrhea, diarrhea, abdominal pain, anemia, and weight loss, also referred to as the somatostatinoma syndrome. Although 7% of pancreatic NET in patients with MEN1 secrete somatostatin,

the somatostatinoma syndrome does not appear to have been reported in a patient with MEN1 (4, 17).

Pituitary tumors

Clinical manifestations and diagnosis

The incidence of pituitary tumors in patients with MEN1 varies from 15 to 50% in different series (Table 1) (11, 12, 50, 62, 63). These occur as early as 5 yr of age or as late as the ninth decade, and the mean \pm SD age of onset has been reported to be 38.0 ± 15.3 yr (12, 64). MEN1 pituitary adenomas have been reported to occur more frequently in women than men, and significantly more of these were macroadenomas, *i.e.* diameter greater than 1 cm (MEN1 *vs.* non-MEN1 macroadenomas = 85 *vs.* 42%; $P < 0.001$) (12). Moreover, about one third of these pituitary tumors showed at histology invasive features such as infiltration of tumor cells through surrounding normal juxtatumoral pituitary tissue. However, no specific histological parameters were reported to differentiate between MEN1 and non-MEN1 pituitary tumors (11). Despite the apparent larger size, more aggressive behavior and reduced response to therapy, no increased prevalence of pituitary carcinoma is observed in MEN1 (63). Approximately 60% of MEN1-associated pituitary tumors secrete prolactin, fewer than 25% secrete GH, 5% secrete ACTH, and the remainder appear to be nonfunctioning, with some secreting glycoprotein subunits (Table 1) (11, 62, 63), although the occurrence of nonfunctioning adenomas has been reported to be higher at approximately 25% in a large kindred from Tasmania (65). However, pituitary tumors derived from MEN1 patients may exhibit immunoreactivity to several hormones, and in particular there is a higher occurrence of somatolactotrophinomas (11). Indeed, plurihormonal expression is more frequently observed in MEN1-associated pituitary tumors compared with non-MEN1 pituitary tumors (11, 12). Pituitary tumors, which are usually prolactinomas, may be the first manifestation of MEN1 in approximately 15% of patients, and somatotrophinomas occur more often in patients older than 40 yr (4, 12, 50), although there does not appear to be any clear genotype-phenotype correlation (11). Fewer than 3% of patients with anterior pituitary tumors will have MEN1 (63, 66). Clinical manifestations of these tumors in patients with MEN1 are similar to those in patients with sporadic pituitary tumors without MEN1 and depend on the hormone secreted and the size of the pituitary tumor. Thus, patients may have symptoms of hyperprolactinemia (*e.g.* amenorrhea, infertility, and galactorrhea in women, and impotence and infertility in men) or have acromegaly or Cushing's disease. In addition, enlarging pituitary tumors may compress adjacent structures such as the optic chiasm or normal pituitary

tissue and may cause visual disturbances, and/or hypopituitarism. In a *MEN1* mutation carrier, who would be considered to be at high risk of developing tumors, periodic biochemical monitoring should include measurement of serum prolactin and IGF-I levels, as well as MRI (45) of the pituitary (Table 2). In patients with abnormal results, hypothalamic-pituitary testing should characterize further the nature of the pituitary lesion and its effects on the secretion of other pituitary hormones.

Treatment

Treatment of pituitary tumors in patients with *MEN1* has consisted of the use of therapies similar to those in patients without *MEN1* and consists of appropriate medical therapy (e.g. bromocriptine or cabergoline for prolactinoma; or octreotide or lanreotide for somatotrophinoma) or selective transsphenoidal adenectomy if feasible, with radiotherapy reserved for residual unresectable tumor tissue. However, pituitary tumors in *MEN1* patients have been reported to be more aggressive and less responsive to medical or surgical treatments (11, 12, 63, 65). Thus, treatment in *MEN1* patients with hormonally secreting pituitary adenomas was significantly less effective in restoring the hypersecretion of hormones to normal (*MEN1* vs. non-*MEN1* patients = 42 vs. 90%; $P < 0.001$) (12). Furthermore, a separate analysis of the 85 prolactinomas in *MEN1* patients revealed that treatment was successful in normalizing plasma prolactin concentrations in only 37 (44%) patients. Thus, although few studies have specifically focused on the treatment of *MEN1*-associated pituitary tumors, it is likely that surgery will be required more frequently in the treatment of *MEN1*-associated than in non-*MEN1* pituitary adenomas. The outcomes of treatment of other types of pituitary tumor have not been separately reported in sufficient numbers to compare reliably with the equivalent sporadic cases.

Associated tumors

Patients with *MEN1* may have tumors involving tissues other than the parathyroid glands, pancreas, and pituitary. Thus, carcinoid, adrenal cortical tumors, facial angiofibromas, collagenomas, thyroid tumors, lipomatous tumors, and meningiomas have been described in association with *MEN1* (Table 1).

Carcinoid tumors

Clinical manifestations and diagnosis

Carcinoid tumors occur in more than 3% of patients with *MEN1* (Table 1). The carcinoid tumor may be located in the bronchi, gastrointestinal tract, pancreas, or thymus. Bronchial carcinoids in patients with *MEN1* occur predominantly in women (male/female ratio, 1:4). In

contrast, thymic carcinoids in European patients with *MEN1* occur predominantly in men (male/female ratio, 20:1), with cigarette smokers having a higher risk for these tumors (4, 67–69); whereas in Japanese *MEN1* patients, thymic carcinoids have a less-marked gender difference (male/female ratio, 2:1) (13). The course of thymic carcinoids in *MEN1* appears to be particularly aggressive. The presence of thymic tumors is reported to be associated with a significantly increased risk of death in patients with *MEN1* (hazard ratio, 4.29), which contrasts with the situation with bronchial carcinoids where an increased risk of death has not been reported (17). The median survival after the diagnosis of a thymic tumor is reported to be approximately 9.5 yr, with 70% of patients dying as a direct result of the tumor (69). At the time of diagnosis, most patients are asymptomatic and do not have clinical features of the carcinoid syndrome. Importantly, no hormonal or biochemical abnormality (e.g. plasma chromogranin A) is consistently observed in individuals with thymic or bronchial carcinoid tumors. Thus, screening for these tumors is dependent on radiological imaging (70). The optimum method for screening has not been established. CT and MRI are reported to be sensitive at detecting thymic and bronchial tumors, although with CT scanning there is concern over the exposure to repeated doses of ionizing radiation (69, 70). Octreotide scintigraphy may also reveal some thymic and bronchial carcinoids, although at present there is insufficient evidence to recommend its routine use (69). Currently we suggest CT or MRI imaging every 1–2 yr for the early detection of thymic and bronchial masses (Table 2) (17, 70, 71). Gastric carcinoids, of which the type II gastric enterochromaffin-like (ECL) cell carcinoids (ECLomas) are associated with *MEN1* and ZES, may be detected incidentally at the time of gastric endoscopy for dyspeptic symptoms in *MEN1* patients. These tumors, which may be found in over 70% of *MEN1* patients, are usually multiple and smaller than 1.5 cm (72).

Treatment

Surgical removal of carcinoids, if resectable, is the treatment of choice. It is noteworthy that thymic carcinoids have been reported to occur in patients who have undergone prophylactic transcervical thymectomy, suggesting that after such a procedure, surveillance imaging is still required (69). For unresectable tumors and those with metastatic disease, treatment with radiotherapy or chemotherapeutic agents (e.g. cisplatin, etoposide) may be used (73). In addition, somatostatin analogs, such as octreotide or lanreotide, have resulted in improvements in symptoms and regression of some tumors (74). Little is known about the malignant potential of gastric type II ECLomas, but treatment with somatostatin analogs, such

as octreotide or lanreotide, has resulted in regression of these ECLomas (72, 74, 75).

Adrenocortical tumors

Clinical manifestations and diagnosis

The incidence of asymptomatic adrenocortical tumors in patients with MEN1 is reported to be 20–73%, depending on the radiological screening methods employed (Table 1) (45, 76–78). Most of these tumors, which include cortical adenomas, hyperplasia, multiple adenomas, nodular hyperplasia, cysts, or carcinomas, are nonfunctioning (76). Indeed, less than 10% of patients with enlarged adrenal glands have hormonal hypersecretion, and among these, primary hyperaldosteronism and ACTH-independent Cushing's syndrome are the most commonly encountered (76). Occasionally, hyperandrogenemia may occur in association with adrenocortical carcinoma, and the occurrence of pheochromocytoma in association with MEN1 is rare. Biochemical investigation (*e.g.* plasma renin and aldosterone concentrations, low-dose dexamethasone suppression test, urinary catecholamines and/or metanephrines) should be undertaken for those with symptoms or signs suggestive of functioning adrenal tumors, or for those with tumors larger than 1 cm. The incidence of adrenocortical carcinoma is reported to be approximately 1% in MEN1 patients but increases to approximately 13% in MEN1 patients with adrenal tumors larger than 1 cm (76). Thus, it is important that MEN1 patients with adrenal tumors are offered an annual imaging screen (Table 2) (76–78), and tumors that display atypical radiological characteristics (*e.g.* increased Hounsfield unit on unenhanced CT scan), significant growth, or are larger than 4 cm are considered for surgical removal.

Treatment

Consensus has not been reached about the management of MEN1-associated nonfunctioning tumors because the majority of nonfunctioning adrenal tumors are benign. However, the risk of malignancy is increased if the tumor has a diameter greater than 4 cm, although adrenocortical carcinomas have been identified in tumors of less than 4 cm in patients with MEN1. We therefore suggest surgery for adrenal tumors that: are more than 4 cm in diameter; have atypical or suspicious radiological features and are 1–4 cm in diameter; or show significant measurable growth over a 6-month interval (76–78). The treatment of functioning (*i.e.* secreting) adrenal tumors in MEN1 patients is similar to that for tumors occurring in non-MEN1 patients.

Meningioma

Central nervous system tumors including ependymomas, schwannomas, and meningiomas have been reported

in MEN1 patients (Table 1) (14). Meningiomas were found in less than 10% of MEN1 patients (Table 1) who had other clinical manifestations of MEN1 (*e.g.* primary hyperparathyroidism) for more than 15 yr. The majority of meningiomas were not associated with symptoms, and 60% did not enlarge (14). The treatment of MEN1-associated meningiomas is similar to that occurring in non-MEN1 patients.

Cutaneous manifestations of MEN1

Lipomas

Subcutaneous lipomas may occur in more than 33% of patients with MEN1 (Table 1) and are frequently multiple. In addition, visceral, pleural, or retroperitoneal lipomas may occur in patients with MEN1 (1). Management is conservative. However, when surgically removed for cosmetic reasons, they typically do not recur.

Facial angiofibromas and collagenomas

Studies of patients with MEN1 have revealed that the occurrence of multiple facial angiofibromas may range from 22 to 88%, and occurrence of collagenomas may range from 0 to 72% (Table 1) (4, 79). These cutaneous findings, which occur with a higher frequency in patients with MEN1, may provide a useful means for possible pre-symptomatic diagnosis of MEN1 in the relatives of a patient with MEN1. Treatment for these cutaneous lesions is usually not required.

Thyroid tumors

Thyroid tumors comprising adenomas, colloid goiters, and carcinomas have been reported to occur in more than 25% of patients with MEN1. However, the prevalence of thyroid disorders in the general population is high, and it has been suggested that the association of thyroid abnormalities in patients with MEN1 may be incidental and not significant. The treatment of thyroid tumors in MEN1 patients is similar to that for non-MEN1 patients.

Genetic testing and screening in MEN1

MEN1 gene

The *MEN1* gene is located on chromosome 11q13 and consists of 10 exons, which encode a 610-amino acid protein, menin (80, 81), that regulates transcription, genome stability, cell division, and proliferation (4, 16). However, the precise role of menin in tumorigenesis as well as new therapeutic targets, remains to be established. Inheritance of a germline *MEN1* mutation predisposes an individual to developing a tumor that arises after a somatic mutation, which may be a point mutation or more commonly a deletion, leading to loss of heterozygosity (LOH) in the tumor DNA, consistent with the Knudson two-hit hypothesis and a

tumor suppressor role for menin (4, 16). Thus, the nontumor cells (e.g. leukocytes) of a patient will be heterozygous in having both the wild-type (normal) and mutant alleles of the *MEN1* gene, whereas tumor cells, which display LOH in more than 90% of cases, will have only the mutant *MEN1* allele. In the less than 10% of *MEN1*-associated tumors in which LOH is not observed, inactivation of the wild-type allele most commonly occurs as a result of a point mutation or a small deletion or insertion within the coding region or splice sites of the *MEN1* gene.

MEN1 germline mutations

A total of 1336 mutations of the *MEN1* gene have been characterized, and 1133 germline and 203 somatic mutations have been reported in the first decade after identification of the gene (16). The 1133 germ-line mutations of the *MEN1* gene, which consist of 459 different mutations are scattered throughout the entire 1830-bp coding region and splice sites of the *MEN1* gene (16). Most (75%) of the *MEN1* germline mutations are inactivating, consistent with those expected in a tumor-suppressor gene. Mutations at nine sites in the *MEN1* gene accounted for over 20% of all the germ-line mutations (Table 1) (16). *MEN1* mutations and clinical manifestations of the disorder appear not to correlate. The apparent lack of genotype/phenotype correlation, which contrasts with the situation in patients with *MEN2* (Table 1), together with the wide diversity of mutations in the 1830-bp coding region of the *MEN1* gene, makes mutational analysis for diagnostic purposes in *MEN1* more difficult than that for *MEN2* (13, 16). More than 10% of *MEN1* germline mutations arise *de novo* and may be transmitted to subsequent generations (16). When a previously unknown missense mutation or in-frame deletion is identified, molecular diagnosis of *MEN1* may not be so simple because the pathogenicity of these mutations is not clear *per se*. Notably, between 5 and 25% of patients with *MEN1* may not harbor germline mutations in the *MEN1* gene coding region, and these individuals may have whole or partial gene deletions, or mutations in the promoter or untranslated regions, which remain to be investigated (13, 16, 82). We recommend multiplex ligation-dependent probe amplification analysis for the detection of exonic deletions in those individuals in whom an *MEN1* mutation is not identified within the coding region and splice sites (82).

MEN1 gene polymorphisms

Twenty-four different polymorphisms of the *MEN1* gene have been reported (16). It is important to recognize the occurrence of these polymorphisms because they require differentiation from mutations when performing genetic diagnostic analysis, and also because they may oc-

asionally help in segregation analysis in families in whom an *MEN1* mutation has not been identified.

MEN1 tumor somatic mutations

More than 90% of tumors from *MEN1* patients exhibit LOH on 11q13, and this has generally been taken as evidence that the *MEN1* gene acts as a tumor-suppressor gene, consistent with Knudson's two-hit hypothesis (16). However, this LOH represents only one mechanism by which the second hit may occur, with other mechanisms including intragenic deletions and point mutations. Mutational analysis of tumor DNA to identify somatic mutations is of research interest, but it offers little (or no) value in the clinical context because LOH involving chromosome 11q13, the location of *MEN1*, has also been observed in 5 to 50% of sporadic (*i.e.* non-*MEN1*) endocrine tumors (16). For example, a recent study, which determined the exomic sequence of approximately 18,000 protein coding genes in non-*MEN1* pancreatic NET, reported that: 44% of these tumors had somatic inactivating *MEN1* mutations; 43% had mutations of the death domain-associated protein (*DAXX*) and α -thalassemia mental retardation syndrome, X-linked (*ATRX*) that encodes subunits of a transcription/chromatin remodeling complex; and approximately 15% had mutations involving genes (*PTEN*, *TSC2*, and *PIK3CA*) in the mTOR pathway (83). Interestingly, mutations of *MEN1*, *DAXX/ATRX*, or the combination of both *MEN1* and *DAXX/ATRX* were reported to be associated with a prolonged survival relative to those patients whose pancreatic NET lacked these mutations (83).

MEN1 variants

Families with *MEN1* variants appear to develop only some clinical manifestations of *MEN1*. For example, some kindreds may develop parathyroid tumors as the sole endocrinopathy, and this condition is referred to as familial isolated hyperparathyroidism (FIHP). *MEN1* mutations have been reported in 42 FIHP kindreds, 38% of these are missense mutations, and fewer than 31% are nonsense or frame-shift mutations, which would result in a truncated and likely inactivated protein (16, 84). This contrasts significantly ($P < 0.01$) with the observed genotype in *MEN1* patients in whom more than 65% of the germ-line mutations are protein-truncating and about 23% are missense mutations (16). These observations are consistent with a more likely association between missense mutations and the milder FIHP variant, but it is important to note that mutations associated with FIHP are also scattered throughout the coding region and not clustered, similar to that observed for germ-line *MEN1* mutations. Furthermore, the occurrence of protein-truncating mutations in

FIHP patients and particularly deletions, such as the 4 bp, involving codons 83–84, which are identical to those observed in MEN1 patients, makes it difficult to establish an unequivocal phenotype-genotype correlation. However, the sole occurrence of parathyroid tumors in these FIHP families that harbor *MEN1* mutations, similar to those found in other families with MEN1, is remarkable, and mechanisms that determine the altered phenotypic expressions of these mutations remain to be elucidated. MEN1 families with the Burin or prolactinoma variant, which are characterized by a high occurrence of prolactinomas and a low occurrence of gastrinomas (85–87), harbor nonsense mutations (Tyr312Stop and Arg460Stop), and a MEN1 kindred from Tasmania, in whom there was an absence of somatotrophinomas (88), has been reported to have a splice site mutation (c.446–3c→g).

***MEN1* phenocopies and mutation in other genes**

Approximately 5 to 25% of patients with MEN1 may not have mutations of the *MEN1* gene. This variability in detecting *MEN1* mutations may partly be attributable to differences in methods used to identify the mutations; for example, most studies do not systematically examine for large gene deletions, which may be found in up to 33% of patients who do not have coding region mutations (89). In addition, this variability may be due to phenotype ascertainment because some studies have included nonfamilial (*i.e.* sporadic) patients who may have developed only two (or fewer) endocrine tumors, and the detection rate for *MEN1* mutations in these patients was found to be less than 5% (82). Such patients with MEN1-associated tumors but without *MEN1* mutations may represent phenocopies or have mutations involving other genes. Phenocopy refers to the development of disease manifestations usually associated with mutations of a particular gene but instead are due to another etiology, and the occurrence of phenocopies has been reported in 5–10% of MEN1 kindreds (21, 88, 90). These phenocopies occurred in two settings—first, in the context of familial MEN1 (Fig. 1), in which a patient with one MEN1-associated tumor, *e.g.* a prolactinoma, did not have the familial mutation; and second, in the context of clinical MEN1, in which patients with two MEN1-associated tumors, who did not have an *MEN1* mutation, were demonstrated to have involvement of other genes. These genes may include: *CDC73*, which encodes parafibromin, whose mutations result in the hyperparathyroid-jaw tumor (HPT-JT) syndrome; the *CaSR*, whose mutations result in familial benign hypocalciuric hypercalcemia (FBHH) (90); and the aryl hydrocarbon receptor-interacting protein (*AIP*), a tumor suppressor located on chromosome 11q13 whose mutations are associated with fa-

miliar isolated pituitary adenomas (FIPA) (91). FIPA, which may account for approximately 2.5% of all pituitary adenomas, constitutes a heterogeneous disorder characterized by familial pituitary adenomas that are most commonly somatotrophinomas, but may also be prolactinomas, ACTH-secreting and nonfunctioning pituitary adenomas (92, 93); and *AIP* mutations may occur in approximately 20% of FIPA patients and approximately 30–50% of those with familial acromegaly (94–96). The occurrence of MEN1 phenocopies may confound the diagnosis of MEN1 (Fig. 1) in an individual, and it therefore appears advisable to offer genetic testing to determine the *MEN1* mutation status to symptomatic family members within a MEN1 kindred, as well as to all index cases (*i.e.* patient) with two or more endocrine tumors. If a *MEN1* mutation is not identified in the index case with two or more endocrine tumors, then clinical and genetic tests for other disorders such as HPT-JT, FBHH, or FIPA should be considered because these patients may represent phenocopies for MEN1 (Fig. 2).

The involvement of another gene, *CDKN1B*, which encodes the 196-amino acid cyclin-dependent kinase inhibitor p27kip1, has also been reported by studies of unrelated patients who did not have *MEN1* mutations but did have MEN1-associated tumors (66, 97, 98). *CDKN1B* mutations have been reported in approximately 1.5% of these patients and their families, and this condition has been referred to as MEN4 (Table 1). In addition, germline mutations of the cyclin-dependent kinase inhibitors p15, p18, and p21 may be probable causes of MEN1 in approximately 1, 0.5, and 0.5% of patients, respectively (99).

***MEN1* mutational analysis in clinical practice**

MEN1 mutational analysis is helpful in clinical practice in several ways that include: 1) confirmation of the clinical diagnosis; 2) identification of family members who harbor the *MEN1* mutation and require screening for tumor detection and early/appropriate treatment; and 3) identification of the 50% of family members who do not harbor the familial germline *MEN1* mutation and can therefore be reassured and alleviated of the anxiety burden of developing future tumors. This latter aspect cannot be overemphasized because it helps to reduce the cost to the individuals and their children and also to the health services in not having to undertake unnecessary biochemical and radiological investigations (Table 2) (21). Thus, *MEN1* mutational analysis can be useful in clinical practice (Table 3).

Indications for MEN1 mutational analysis

MEN1 mutational analysis should be undertaken in: 1) an index case with two or more MEN1-associated endocrine tumors (*i.e.* parathyroid, pancreatic, or pituitary tu-

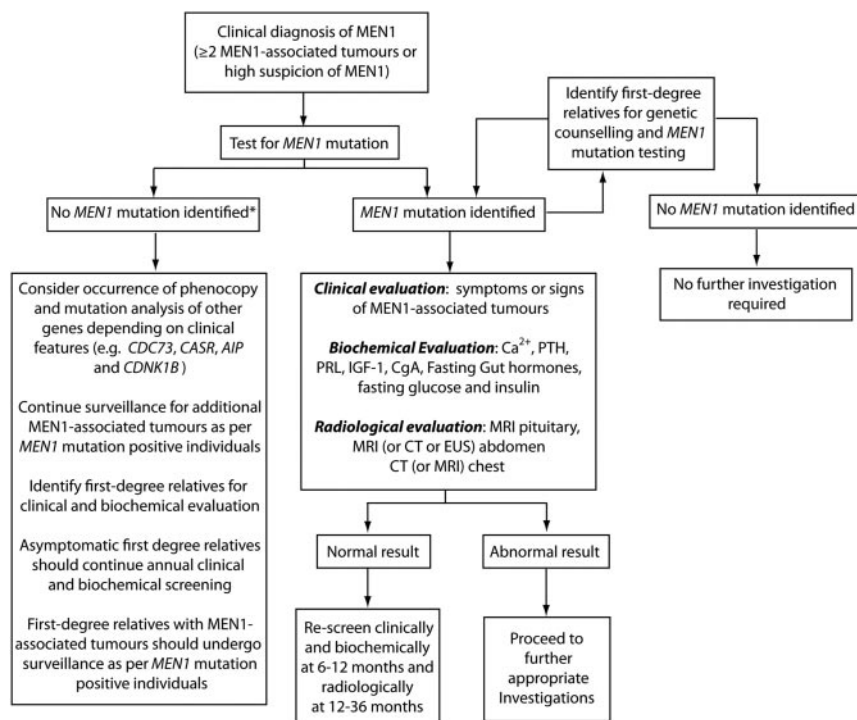


FIG. 2. An approach to screening in MEN1. Index cases, or individuals in whom there is a high suspicion of clinical MEN1 (e.g. multigland parathyroid disease, parathyroid + adrenal tumor), should be offered genetic counseling and MEN1 mutation testing. Mutation testing should also be offered to those with familial MEN1 (i.e. individual with one MEN1-associated tumor and a first-degree relative with a known MEN1 mutation). The identification of a germline MEN1 mutation should prompt entry into a periodic clinical, biochemical, and radiological screening program. At the same time, first-degree relatives should be identified and offered genetic counseling and MEN1 mutation testing. Individuals who have inherited the MEN1 mutation should enter periodic screening, even if asymptomatic. First-degree relatives who have not inherited the MEN1 mutation require no further follow-up and may be alleviated of the anxiety associated with the development of MEN1-associated tumors. For index cases, in whom a MEN1 mutation, which includes testing for partial or whole gene deletions (*asterisk*), is not identified, additional genetic testing may be required depending on the specific clinical features. This may include examination for mutations in genes associated with familial parathyroid syndromes including CDC73 associated with the HPT-JT and the calcium sensing receptor (CASR) associated with FBHH; or cyclin-dependent kinase 1B (CDKN1B) and AIP which are rarely identified in those with clinical MEN1. Up to 10% of kindreds with clinical MEN1 may harbor phenocopies emphasizing the importance of accurate genetic evaluation. For MEN1 kindreds in whom no MEN1 mutation is identified, a pragmatic approach is to offer clinical, biochemical, and radiological screening to those with clinical manifestations of disease and to offer annual clinical and biochemical screening to asymptomatic first-degree relatives. Ca²⁺, Calcium; PRL, prolactin; CgA, chromogranin A; EUS, endoscopic ultrasound.

mors); 2) asymptomatic first-degree relatives of a known MEN1 mutation carrier; 3) a first-degree relative of an MEN1 mutation carrier expressing familial MEN1 (i.e. having symptoms, signs, biochemical or radiological evidence for one or more MEN1-associated tumors); or 4) in patients with suspicious or atypical MEN1, which includes individuals with parathyroid adenomas occurring before the age of 30 yr; or multigland parathyroid disease, gastrinoma, or multiple pancreatic NET at any age; or individuals who have two or more MEN1-associated tumors that are not part of the classical triad of parathyroid, pancreatic islet, and anterior pituitary tu-

mors (e.g. parathyroid tumor plus adrenal tumor) (Table 3) (21).

Such mutational analysis may be undertaken in children within the first decade because children with MEN1 tumors have been reported by the age of 10 yr, and appropriate intervention in the form of biochemical testing or treatment or both has been considered. For example, the earliest reported ages of onset for a MEN1-associated pituitary tumor, parathyroid tumor, insulinoma, and nonfunctioning pancreatic NET more than 2 cm in size are 5, 8, 8, and 12 yr, respectively. Furthermore, one study of 12 children under the age of 20 yr from MEN1 families has reported that more than 40% of children will have developed one or more MEN1-associated tumors (40). These studies suggest that early identification of at risk individuals through mutation testing may be beneficial, although further studies that also evaluate a more conservative clinical surveillance approach with cost-benefit analysis are required. Thus, a DNA test identifying an individual, who may be an asymptomatic relative of a patient with MEN1, as a mutant gene carrier is likely to lead to earlier and more frequent biochemical and radiological screening rather than to immediate medical or surgical treatment. In contrast, those relatives who do not harbor the MEN1 mutation have their risk of developing MEN1-associated endocrine tumors markedly decreased from one in two for an autosomal dominant disorder, to that of the general population, thereby freeing these relatives

without the MEN1 mutation from the requirement for further repeated clinical investigations. Thus, identification of MEN1 mutations may be of help in the clinical management of patients and their families with this disorder. Finally, MEN1 mutational analysis in a symptomatic family member (i.e. an individual already showing a clinical manifestation of MEN1) from a family with a known MEN1 mutation has been challenged as being unnecessary to establish the diagnosis of MEN1. However, two studies have reported that 5–10% of MEN1 kindreds have the occurrence of phenocopies, which may confound

TABLE 3. Suggested approach for *MEN1* mutational analysis in a clinical setting

Value in clinical setting
Aid in confirming the diagnosis
Identify mutation carriers in a family for screening and development of tumors, thereby facilitating early treatment
Identify the 50% of family members who do not harbor the <i>MEN1</i> mutation, thereby alleviating the anxiety and burden of disease from them and their progeny
Who should be tested?
In an index case
Meeting the clinical criteria for <i>MEN1</i> (<i>i.e.</i> two or more <i>MEN1</i> -associated tumors or a diagnosis of familial <i>MEN1</i>)
Suspicious (<i>i.e.</i> multiple parathyroid adenomas before the age of 40 yr; recurrent hyperparathyroidism; gastrinoma or multiple pancreatic NET at any age) or atypical for <i>MEN1</i> (<i>i.e.</i> development of two nonclassical <i>MEN1</i> -associated tumors, <i>e.g.</i> parathyroid and adrenal tumor)
A first-degree relative of family member with known <i>MEN1</i> mutation
Asymptomatic first-degree relative
First-degree relative with familial <i>MEN1</i> (<i>i.e.</i> one <i>MEN1</i> -associated tumor)
When should testing be undertaken?
As early as possible (<i>e.g.</i> before 5 yr of age for asymptomatic individuals)
Where should test be performed?
In accredited department/laboratory undertaking DNA testing of <i>MEN1</i> gene

Adapted from P. J. Newey and R. V. Thakker: Role of multiple endocrine neoplasia type 1 mutational analysis in clinical practice. *Endocr Pract* 17(Suppl 3):8–17, 2011 (21), with permission. © American Association of Clinical Endocrinologists.

the diagnosis (Fig. 1), and therefore we suggest that *MEN1* family members with one *MEN1*-associated tumor should be offered *MEN1* mutation analysis.

***MEN1* mutational analysis in young patients with nonfamilial single endocrine tumors**

MEN1 germline mutational analysis should be considered in those presenting at an early age with a single, apparently sporadic *MEN1*-associated tumor (Table 3). The occurrence of germline *MEN1* mutations in all patients with sporadic, nonfamilial parathyroid adenomas is 1%; in gastrinomas, 5%; in prolactinomas, 1%; and in foregut carcinoids, 2%. Investigations by two studies (100, 101) for germline *MEN1* mutations in patients developing nonfamilial (*i.e.* sporadic) parathyroid tumors before the age of 40 yr has found the occurrence of such mutations in only three of 36 patients. All three of these patients had multigland parathyroid disease, whereas the majority (~95%) of the patients without *MEN1* mutations had solitary parathyroid adenomas. We suggest performing *MEN1* mutational testing in patients who are below 40 yr of age and have primary hyperparathyroidism due to multigland disease. The occurrence rates of germline *MEN1* mutations in individuals presenting with a single apparent nonfamilial (*i.e.* sporadic) pancreatic NET at similarly

younger age has not been established, and we suggest that *MEN1* mutational analysis should also be considered in those with gastrinoma or multiple pancreatic NET.

Detection of *MEN1* tumors

Biochemical screening for the development of *MEN1* tumors in asymptomatic members of families with *MEN1* is likely to be of benefit in as much as earlier diagnosis and treatment of these tumors may help reduce morbidity and mortality (Fig. 2). Age-related penetrance (*i.e.* the proportion of gene carriers manifesting symptoms or signs of the disease by a given age) has been ascertained, and the mutation appears to be nonpenetrant in those younger than 5 yr (1, 4, 64). Thereafter, the mutant *MEN1* gene has a high penetrance, more than 50% penetrant by 20 yr of age and more than 95% by 40 yr (1, 4, 7). Screening for *MEN1* tumors is difficult because clinical and biochemical manifestations in members of any one family are not uniformly similar. Attempts to screen for development of *MEN1* tumors in the asymptomatic relatives of an affected individual have depended largely on measuring serum concentrations of calcium, gastrointestinal hormones (*e.g.* gastrin), prolactin, and IGF-I, as well as on abdominal and pituitary imaging (Table 2). Parathyroid overactivity causing hypercalcemia is almost invariably the first manifestation of the disorder and has become a useful and easy biochemical screening investigation. In addition, hyperprolactinemia, which may be asymptomatic, may represent the first manifestation in approximately 15% of patients and may thus also be a helpful and easy biochemical screening investigation. Pancreatic involvement in asymptomatic individuals has been detected by measuring fasting plasma concentrations of gastrin, pancreatic polypeptide, glucagon, and chromogranin A and by abdominal imaging (4, 102).

We suggest that individuals at high risk for *MEN1* (*i.e.* mutant gene carriers) undergo biochemical screening (Fig. 2) at least once per annum and also have baseline pituitary and abdominal imaging (*e.g.* MRI or CT), which should then be repeated at 1- to 3-yr intervals (Table 2). Screening should possibly commence in early childhood because the disease has developed in some individuals by the age of 5 yr, and it should be repeated throughout life because the disease may not manifest in some individuals until the eighth decade. Screening history and physical examination should be directed toward eliciting symptoms and signs of hypercalcemia, nephrolithiasis, peptic ulcer disease, neuroglycopenia, hypopituitarism, galactorrhea and amenorrhea in women, acromegaly, Cushing's disease, and visual field loss and the presence of sc lipomas, angiofibromas, and collagenomas. We suggest that biochemical screening should include estimations of serum calcium, PTH, gastrointestinal hormones (*e.g.* gastrin,

insulin with a fasting glucose, glucagon, VIP, and pancreatic polypeptide), chromogranin A, prolactin, and IGF-I in all individuals, and more specific endocrine-function tests should be undertaken in individuals who exhibit symptoms or signs suggestive of a clinical syndrome (Table 2). We suggest that radiological screening should include an MRI (or CT scanning) of the pancreas, adrenal glands, and pituitary, initially as a baseline and then every 1 to 3 yr, as well as imaging for thymic and bronchial carcinoids using CT or MRI every 1–2 yr (Table 2).

Organization of care

We recommend that patients with MEN1 and their families are cared for by centers with expertise in the management of MEN1 because the disorder is associated with a wide spectrum of clinical manifestations as well as complexities in its diagnosis, screening, and treatment. In addition, an endocrinologist with expertise in MEN syndromes should be responsible for coordinating overall care of the patient and families. We suggest that patients with MEN1-associated tumors should be reviewed regularly (*e.g.* at 3- to 6-month intervals or as deemed appropriate by the clinical features) and that asymptomatic first-degree relatives should be reviewed annually with appropriate clinical, biochemical, and radiological screening as outlined in these guidelines (Table 2). Patients should remain under lifelong review at a specialist center. In addition, there should be direct access to a wide-ranging MDT including endocrinologists and gastroenterologists; endocrine, hepatobiliary, cardiothoracic, and pituitary surgeons with specific expertise in the surgical management of MEN1-associated tumors; oncologists with appropriate experience in gastropancreatic NET, as well as thymic and bronchial carcinoid tumors; radiologists, including those with expertise in nuclear medicine; histopathologists with expertise in the staging and grading of NET; and clinical geneticists for genetic diagnosis and counseling. In addition, we specifically recommend that all gastropancreatic NET, thymic, and bronchial carcinoids are discussed by an appropriately qualified neuroendocrine MDT. This approach improves communication between specialties, leading directly to improved patient care. In view of the diverse therapeutic strategies available for treatment of MEN1-associated tumors, centers managing patients with MEN1 must have access to facilities to provide such treatments. Furthermore, we suggest that patient details are entered in an ethically approved local or national MEN1 registry.

Patients with suspected MEN1 and their relatives should be referred to a clinical genetics service (Fig. 2 and Table 3). Genetic counseling should be provided to all patients before potential mutation testing so that informed decisions can be

made. Individuals with MEN1 should have access to information about the condition. At each consultation, decisions regarding diagnosis and treatment should be discussed with each patient. Access to a specialist nurse with expertise in the management of MEN1-associated tumors, to provide additional information and support, is likely to be beneficial to patients. Additional support and information may be obtained through national and international patient support groups [*e.g.* the Association of Multiple Endocrine Neoplasia Disorders (AMEND), UK].

Future directions

Significant advances have been made in the diagnosis of MEN1 and in the early detection of tumors through periodic screening programs, which include sensitive radiological modalities. However, the optimal treatment of many MEN1-associated tumors still remains to be defined because there is a paucity of clinical trials examining the outcomes of specific therapies for the treatment of MEN1-associated tumors. However, it should be noted that such trials may be difficult to pursue because recruitment of appropriate numbers of MEN1 patients to power the trial may not be possible from single national centers. To overcome this, the development of national and international MEN1 registries and collaborations is encouraged. The success of such an approach is well illustrated by the results of clinical trials investigating the use of TRK inhibitors for MTC (103) and pancreatic NET, and mTOR inhibitors for pancreatic NET (59, 60). Additional values of such registries have also been demonstrated by determining important information on different aspects that include the natural history of adrenal lesions in MEN1 and the role of surgery for nonfunctioning pancreatic NET (13, 54, 76). Further molecular understanding of MEN1 tumor biology is also required for establishing better underlying rationales for the increasing number of novel and selective treatments. This is illustrated by the findings of two recent studies that hold promise for the emergence of therapeutic targets that disrupt the reported interaction between menin and the mixed lineage leukemia protein 1 (MLL1), which is a histone H3 lysine 4 methyltransferase and functions as an oncogenic cofactor to up-regulate gene transcription (104). The crystal structures of human menin in its free form and in complexes with MLL1 have shown that menin contains a deep pocket that binds to short peptide of MLL1 (104). High-throughput screening studies to identify compounds that target menin and suppress its interaction with MLL1 have identified that thienopyrimidine has such functions (105, 106). Further structure activity analyses led to generation of two thienopyrimidine analogs, which bind to wild-type menin but not menin mutants that involve the interaction

site with MLL (105, 106). Such further studies may help to identify other analogs that could represent future pharmacological treatments for MEN1 tumors. Another possible approach is to undertake molecular phenotyping of tumors because this may provide important insights that could guide treatment; for example, molecular phenotyping of pancreatic NET could identify those tumors with an activated mTOR pathway and which are reported to be associated with a poor prognosis, so that earlier treatment with mTOR inhibitors may be started and its effect on clinical outcomes assessed. In addition, non-MEN1 patients whose pancreatic NET have MEN1 or DAXX/ATRX mutations have a better prognosis than those with mutations of genes within the mTOR signaling pathway (83), and this finding requires a prospective evaluation in MEN1 patients. Thus, it is important that research efforts are encouraged, including the establishment of biobanks of MEN1-associated tumors. Finally, patients should be made aware of the importance of ongoing research and encouraged to engage in these studies, consistent with the goal of providing personalized therapies.

Web sites of centers offering MEN1 genetic testing

Contact information for some centers offering genetic testing for MEN1 can be found on the following web sites: <http://www.ncbi.nlm.nih.gov/sites/GeneTests/> (giving details of centers in Canada, Denmark, Greece, Israel, Japan, and United States); <http://www.orpha.net/consor/cgi-bin/index.php> or www.eddnl.com (giving details of centers in Austria, Belgium, Denmark, Finland, France, Germany, Holland, Ireland, Italy, Norway, Portugal, Spain, Sweden, Switzerland, and the United Kingdom).

Acknowledgments

R.V.T., P.J.N., and G.V.W. are grateful to the Medical Research Council (MRC), UK, and the National Institute for Health Research (NIHR), UK, for support.

Address all correspondence and requests for reprints to: Rajesh V. Thakker, Academic Endocrine Unit, Nuffield Department of Clinical Medicine, University of Oxford, Oxford Centre for Diabetes, Endocrinology and Metabolism (OCDEM), Churchill Hospital, Headington, Oxford OX3 7LJ, United Kingdom. E-mail: rajesh.thakker@ndm.ox.ac.uk. Or Maria Luisa Brandi, Department of Internal Medicine, University of Florence, Florence, Italy. E-mail: m.brandi@dmf.unifi.it.

R.V.T., P.J.N., G.V.W. were supported by funding from the MRC, UK (Grants G9825289/2004 and G1000467/2010), and the NIHR, UK.

Material in this study was previously published in Refs. 4, 5, 16, 21, and 90.

Disclosure Summary: The authors declare no conflicts of interest.

References

- Brandi ML, Gagel RF, Angeli A, Bilezikian JP, Beck-Peccoz P, Bordi C, Conte-Devolx B, Falchetti A, Gheri RG, Libroia A, Lips CJ, Lombardi G, Mannelli M, Pacini F, Ponder BA, Raue F, Skogseid B, Tamburrano G, Thakker RV, Thompson NW, Tomasetti P, Tonelli F, Wells Jr SA, Marx SJ 2001 Guidelines for diagnosis and therapy of MEN type 1 and type 2. *J Clin Endocrinol Metab* 86:5658–5671
- Atkins D, Best D, Briss PA, Eccles M, Falck-Ytter Y, Flottorp S, Guyatt GH, Harbour RT, Haugh MC, Henry D, Hill S, Jaeschke R, Leng G, Liberati A, Magrini N, Mason J, Middleton P, Mrukowicz J, O'Connell D, Oxman AD, Phillips B, Schünemann HJ, Edejer TT, Varonen H, Vist GE, Williams Jr JW, Zaza S 2004 Grading quality of evidence and strength of recommendations. *BMJ* 328:1490
- Swiglo BA, Murad MH, Schünemann HJ, Kunz R, Vigersky RA, Guyatt GH, Montori VM 2008 A case for clarity, consistency, and helpfulness: state-of-the-art clinical practice guidelines in endocrinology using the grading of recommendations, assessment, development, and evaluation system. *J Clin Endocrinol Metab* 93:666–673
- Thakker RV 2010 Multiple endocrine neoplasia type 1. In: De Groot L, Jameson JL, eds. *Endocrinology*. 6th ed. Philadelphia: Elsevier; 2719–2741
- Thakker RV 2011 Multiple endocrine neoplasia type 1 (MEN1). In: Robertson RP, Thakker RV, eds. *Translational endocrinology and metabolism*. Vol 2. Chevy Chase, MD: The Endocrine Society; 13–44
- Thakker RV 1998 Multiple endocrine neoplasia—syndromes of the twentieth century. *J Clin Endocrinol Metab* 83:2617–2620
- Machens A, Schaaf L, Karges W, Frank-Raue K, Bartsch DK, Rothmund M, Schneyer U, Goretzki P, Raue F, Dralle H 2007 Age-related penetrance of endocrine tumours in multiple endocrine neoplasia type 1 (MEN1): a multicentre study of 258 gene carriers. *Clin Endocrinol (Oxf)* 67:613–622
- Thomas-Marques L, Murat A, Delemer B, Penfornis A, Cardot-Bauters C, Baudin E, Niccoli-Sire P, Levoir D, Choplin Hdu B, Chabre O, Jovenin N, Cadiot G 2006 Prospective endoscopic ultrasonographic evaluation of the frequency of nonfunctioning pancreaticoduodenal endocrine tumors in patients with multiple endocrine neoplasia type 1. *Am J Gastroenterol* 101:266–273
- Kann PH, Balakina E, Ivan D, Bartsch DK, Meyer S, Klose KJ, Behr T, Langer P 2006 Natural course of small, asymptomatic neuroendocrine pancreatic tumours in multiple endocrine neoplasia type 1: an endoscopic ultrasound imaging study. *Endocr Relat Cancer* 13:1195–1202
- Gibril F, Venzon DJ, Ojeaburu JV, Bashir S, Jensen RT 2001 Prospective study of the natural history of gastrinoma in patients with MEN1: definition of an aggressive and a nonaggressive form. *J Clin Endocrinol Metab* 86:5282–5293
- Trouillas J, Labat-Moleur F, Sturm N, Kujas M, Heymann MF, Figarella-Branger D, Patey M, Mazucca M, Decullier E, Vergès B, Chabre O, Calender A 2008 Pituitary tumors and hyperplasia in multiple endocrine neoplasia type 1 syndrome (MEN1): a case-control study in a series of 77 patients versus 2509 non-MEN1 patients. *Am J Surg Pathol* 32:534–543
- Vergès B, Boureille F, Goudet P, Murat A, Beckers A, Sassolas G, Cougard P, Chambe B, Montvernay C, Calender A 2002 Pituitary disease in MEN type 1 (MEN1): data from the France-Belgium MEN1 multicenter study. *J Clin Endocrinol Metab* 87:457–465
- Sakurai A, Suzuki S, Kosugi S, Okamoto T, Uchino S, Miya A, Imai T, Kaji H, Komoto I, Miura D, Yamada M, Uruno T, Horiuchi K, Miyauchi A, Imamura M, Fukushima T, Hanazaki K, Hirakawa S, Igarashi T, Iwatani T, Kammori M, Katabami T, Katai M, Kikumori T, Kiribayashi K, Koizumi S, Midorikawa S, Miyabe R, Munekage T, Ozawa A, Shimizu K, Sugitani I, Takeyama H, Yamazaki M 2012 Multiple endocrine neoplasia type 1 in Japan:

- establishment and analysis of a multicentre database. *Clin Endocrinol (Oxf)* 76:533–539
14. Asgharian B, Chen YJ, Patronas NJ, Peghini PL, Reynolds JC, Vortmeyer A, Zhuang Z, Venzon DJ, Gibril F, Jensen RT 2004 Meningiomas may be a component tumor of multiple endocrine neoplasia type 1. *Clin Cancer Res* 10:869–880
 15. Flanagan DE, Armitage M, Clein GP, Thakker RV 1996 Prolactinoma presenting in identical twins with multiple endocrine neoplasia type 1. *Clin Endocrinol (Oxf)* 45:117–120
 16. Lemos MC, Thakker RV 2008 Multiple endocrine neoplasia type 1 (MEN1): analysis of 1336 mutations reported in the first decade following identification of the gene. *Hum Mutat* 29:22–32
 17. Goudet P, Murat A, Binquet C, Cardot-Bauters C, Costa A, Ruzsniowski P, Niccoli P, Ménégau F, Chabrier G, Borson-Chazot F, Tabarin A, Bouchard P, Delemer B, Beckers A, Bonithon-Kopp C 2010 Risk factors and causes of death in MEN1 disease. A GTE (Groupe d'Etude des Tumeurs Endocrines) cohort study among 758 patients. *World J Surg* 34:249–255
 18. Geerdink EA, Van der Luijt RB, Lips CJ 2003 Do patients with multiple endocrine neoplasia syndrome type 1 benefit from periodical screening? *Eur J Endocrinol* 149:577–582
 19. Dean PG, van Heerden JA, Farley DR, Thompson GB, Grant CS, Harmsen WS, Ilstrup DM 2000 Are patients with multiple endocrine neoplasia type I prone to premature death? *World J Surg* 24:1437–1441
 20. Doherty GM, Olson JA, Frisella MM, Lairmore TC, Wells Jr SA, Norton JA 1998 Lethality of multiple endocrine neoplasia type I. *World J Surg* 22:581–586; discussion 586–587
 21. Newey PJ, Thakker RV 2011 Role of multiple endocrine neoplasia type 1 mutational analysis in clinical practice. *Endocr Pract* 17(Suppl 3):8–17
 22. Norton JA, Fraker DL, Alexander HR, Venzon DJ, Doppman JL, Serrano J, Goebel SU, Peghini PL, Roy PK, Gibril F, Jensen RT 1999 Surgery to cure the Zollinger-Ellison syndrome. *N Engl J Med* 341:635–644
 23. Norton JA, Jensen RT 2007 Role of surgery in Zollinger-Ellison syndrome. *J Am Coll Surg* 205:S34–S37
 24. Imamura M, Komoto I, Ota S, Hiratsuka T, Kosugi S, Doi R, Awane M, Inoue N 2011 Biochemically curative surgery for gastrinoma in multiple endocrine neoplasia type 1 patients. *World J Gastroenterol* 17:1343–1353
 25. Tonelli F, Fratini G, Nesi G, Tommasi MS, Batignani G, Falchetti A, Brandi ML 2006 Pancreatotomy in multiple endocrine neoplasia type 1-related gastrinomas and pancreatic endocrine neoplasias. *Ann Surg* 244:61–70
 26. Schreinemakers JM, Pieterman CR, Scholten A, Vriens MR, Valk GD, Rinkes IH 2011 The optimal surgical treatment for primary hyperparathyroidism in MEN1 patients: a systematic review. *World J Surg* 35:1993–2005
 27. Waldmann J, López CL, Langer P, Rothmund M, Bartsch DK 2010 Surgery for multiple endocrine neoplasia type 1-associated primary hyperparathyroidism. *Br J Surg* 97:1528–1534
 28. Akerström G, Hellman P 2007 Surgery on neuroendocrine tumours. *Best Pract Res Clin Endocrinol Metab* 21:87–109
 29. Fernandez A, Karavitaki N, Wass JA 2010 Prevalence of pituitary adenomas: a community-based, cross-sectional study in Banbury (Oxfordshire, UK). *Clin Endocrinol (Oxf)* 72:377–382
 30. Eller-Vainicher C, Chiodini I, Battista C, Viti R, Mascia ML, Masiroli S, Peracchi M, D'Agruma L, Minisola S, Corbetta S, Cole DE, Spada A, Scillitani A 2009 Sporadic and MEN1-related primary hyperparathyroidism: differences in clinical expression and severity. *J Bone Miner Res* 24:1404–1410
 31. Shih RY, Fackler S, Maturo S, True MW, Brennan J, Wells D 2009 Parathyroid carcinoma in multiple endocrine neoplasia type 1 with a classic germline mutation. *Endocr Pract* 15:567–572
 32. del Pozo C, García-Pascual L, Balsells M, Barahona MJ, Veloso E, González C, Anglada-Barceló J 2011 Parathyroid carcinoma in multiple endocrine neoplasia type 1. Case report and review of the literature. *Hormones (Athens)* 10:326–331
 33. Tonelli F, Marcucci T, Giudici F, Falchetti A, Brandi ML 2009 Surgical approach in hereditary hyperparathyroidism. *Endocr J* 56:827–841
 34. Lambert LA, Shapiro SE, Lee JE, Perrier ND, Truong M, Wallace MJ, Hoff AO, Gagel RF, Evans DB 2005 Surgical treatment of hyperparathyroidism in patients with multiple endocrine neoplasia type 1. *Arch Surg* 140:374–382
 35. Tonelli F, Marcucci T, Fratini G, Tommasi MS, Falchetti A, Brandi ML 2007 Is total parathyroidectomy the treatment of choice for hyperparathyroidism in multiple endocrine neoplasia type 1? *Ann Surg* 246:1075–1082
 36. Norton JA, Venzon DJ, Berna MJ, Alexander HR, Fraker DL, Libutti SK, Marx SJ, Gibril F, Jensen RT 2008 Prospective study of surgery for primary hyperparathyroidism (HPT) in multiple endocrine neoplasia-type 1 and Zollinger-Ellison syndrome: long-term outcome of a more virulent form of HPT. *Ann Surg* 247:501–510
 37. Moyes VJ, Monson JP, Chew SL, Akker SA 2010 Clinical use of cinacalcet in MEN1 hyperparathyroidism. *Int J Endocrinol* 2010: 906163
 38. Anlauf M, Garbrecht N, Henopp T, Schmitt A, Schlenger R, Raffel A, Krausch M, Gimm O, Eisenberger CF, Knoefel WT, Dralle H, Komminoth P, Heitz PU, Perren A, Klöppel G 2006 Sporadic versus hereditary gastrinomas of the duodenum and pancreas: distinct clinicopathological and epidemiological features. *World J Gastroenterol* 12:5440–5446
 39. Dralle H, Krohn SL, Karges W, Boehm BO, Brauckhoff M, Gimm O 2004 Surgery of resectable nonfunctioning neuroendocrine pancreatic tumors. *World J Surg* 28:1248–1260
 40. Newey PJ, Jeyabalan J, Walls GV, Christie PT, Gleeson FV, Gould S, Johnson PR, Phillips RR, Ryan FJ, Shine B, Bowl MR, Thakker RV 2009 Asymptomatic children with multiple endocrine neoplasia type 1 mutations may harbor nonfunctioning pancreatic neuroendocrine tumors. *J Clin Endocrinol Metab* 94:3640–3646
 41. Triponez F, Dosseh D, Goudet P, Cougard P, Bauters C, Murat A, Cadiot G, Niccoli-Sire P, Chayvialle JA, Calender A, Proye CA 2006 Epidemiology data on 108 MEN 1 patients from the GTE with isolated nonfunctioning tumors of the pancreas. *Ann Surg* 243:265–272
 42. Fendrich V, Langer P, Waldmann J, Bartsch DK, Rothmund M 2007 Management of sporadic and multiple endocrine neoplasia type 1 gastrinomas. *Br J Surg* 94:1331–1341
 43. Gibril F, Schumann M, Pace A, Jensen RT 2004 Multiple endocrine neoplasia type 1 and Zollinger-Ellison syndrome: a prospective study of 107 cases and comparison with 1009 cases from the literature. *Medicine* 83:43–83
 44. Turner JJ, Wren AM, Jackson JE, Thakker RV, Meeran K 2002 Localization of gastrinomas by selective intra-arterial calcium injection. *Clin Endocrinol (Oxf)* 57:821–825
 45. Scarsbrook AF, Thakker RV, Wass JA, Gleeson FV, Phillips RR 2006 Multiple endocrine neoplasia: spectrum of radiologic appearances and discussion of a multitechnique imaging approach. *Radiographics* 26:433–451
 46. You YN, Thompson GB, Young Jr WF, Larson D, Farley DR, Richards M, Grant CS 2007 Pancreatoduodenal surgery in patients with multiple endocrine neoplasia type 1: operative outcomes, long-term function, and quality of life. *Surgery* 142:829–836; discussion 836.e1
 47. Norton JA 2005 Surgical treatment and prognosis of gastrinoma. *Best Pract Res Clin Gastroenterol* 19:799–805
 48. Cadiot G, Vuagnat A, Doukhan I, Murat A, Bonnaud G, Delemer B, Thiéfin G, Beckers A, Veyrac M, Proye C, Ruzsniowski P, Mignon M 1999 Prognostic factors in patients with Zollinger-Ellison syndrome and multiple endocrine neoplasia type 1. Groupe d'Etude des Neoplasies Endocriniennes Multiples (GENEM and groupe de Recherche et d'Etude du Syndrome de Zollinger-Ellison (GRESZE). *Gastroenterology* 116:286–293
 49. Norton JA, Alexander HR, Fraker DL, Venzon DJ, Gibril F, Jensen RT 2001 Comparison of surgical results in patients with advanced

- and limited disease with multiple endocrine neoplasia type 1 and Zollinger-Ellison syndrome. *Ann Surg* 234:495–505; discussion 505–506
50. Trump D, Farren B, Wooding C, Pang JT, Besser GM, Buchanan KD, Edwards CR, Heath DA, Jackson CE, Jansen S, Lips K, Monson JP, O'Halloran D, Sampson J, Shalet SM, Wheeler MH, Zink A, Thakker RV 1996 Clinical studies of multiple endocrine neoplasia type 1 (MEN1). *QJM* 89:653–669
 51. Fabbri HC, Mello MP, Soardi FC, Esquiveto-Aun AM, Oliveira DM, Denardi FC, Moura-Neto A, Garmes HM, Baptista MT, Matos PS, Lemos-Marini SH, D'Souza-Li LF, Guerra-Júnior G 2010 Long-term follow-up of an 8-year-old boy with insulinoma as the first manifestation of a familial form of multiple endocrine neoplasia type 1. *Arq Bras Endocrinol Metabol* 54:754–760
 52. Giudici F, Nesi G, Brandi ML, Tonelli F 2012 Surgical management of insulinomas in multiple endocrine neoplasia type 1. *Pancreas* 41:547–553
 53. Langer P, Kann PH, Fendrich V, Richter G, Diehl S, Rothmund M, Bartsch DK 2004 Prospective evaluation of imaging procedures for the detection of pancreaticoduodenal endocrine tumors in patients with multiple endocrine neoplasia type 1. *World J Surg* 28:1317–1322
 54. Triponez F, Goudet P, Dossch D, Cougare J, Bauters C, Murat A, Cadiot G, Niccoli-Sire P, Calender A, Proye CA 2006 Is surgery beneficial for MEN1 patients with small (< or = 2 cm), nonfunctioning pancreaticoduodenal endocrine tumor? An analysis of 65 patients from the GTE. *World J Surg* 30:654–662; discussion 663–664
 55. Kouvaraki MA, Shapiro SE, Cote GJ, Lee JE, Yao JC, Waguespack SG, Gagel RF, Evans DB, Perrier ND 2006 Management of pancreatic endocrine tumors in multiple endocrine neoplasia type 1. *World J Surg* 30:643–653
 56. Lowney JK, Frisella MM, Lairmore TC, Doherty GM 1998 Pancreatic islet cell tumor metastasis in multiple endocrine neoplasia type 1: correlation with primary tumor size. *Surgery* 124:1043–1048, discussion 1048–1049
 57. Bartsch DK, Fendrich V, Langer P, Celik I, Kann PH, Rothmund M 2005 Outcome of duodenopancreatic resections in patients with multiple endocrine neoplasia type 1. *Ann Surg* 242:757–764, discussion 764–766
 58. Anlauf M, Schlenger R, Perren A, Bauersfeld J, Koch CA, Dralle H, Raffel A, Knoefel WT, Weihe E, Ruzniewski P, Couvelard A, Komminoth P, Heitz PU, Klöppel G 2006 Microadenomatosis of the endocrine pancreas in patients with and without the multiple endocrine neoplasia type 1 syndrome. *Am J Surg Pathol* 30:560–574
 59. Yao JC, Shah MH, Ito T, Bohas CL, Wolin EM, Van Cutsem E, Hobday TJ, Okusaka T, Capdevila J, de Vries EG, Tomassetti P, Pavel ME, Hoosen S, Haas T, Lincy J, Lebwohl D, Öberg K 2011 Everolimus for advanced pancreatic neuroendocrine tumors. *N Engl J Med* 364:514–523
 60. Raymond E, Dahan L, Raoul JL, Bang YJ, Borbath I, Lombard-Bohas C, Valle J, Metrakos P, Smith D, Vinik A, Chen JS, Hörsch D, Hammel P, Wiedenmann B, Van Cutsem E, Patyna S, Lu DR, Blankemeister C, Chao R, Ruzniewski P 2011 Sunitinib malate for the treatment of pancreatic neuroendocrine tumors. *N Engl J Med* 364:501–513
 61. Sano T, Yamasaki R, Saito H, Hirose T, Kudo E, Kameyama K, Hiraishi K, Saito S, Hizawa K 1987 Growth hormone-releasing hormone (GHRH)-secreting pancreatic tumor in a patient with multiple endocrine neoplasia type I. *Am J Surg Pathol* 11:810–819
 62. Melmed S 2011 Pathogenesis of pituitary tumors. *Nat Rev Endocrinol* 7:257–266
 63. Beckers A, Betea D, Valdes Socin H, Stevenaert A 2003 The treatment of sporadic versus MEN1-related pituitary adenomas. *J Intern Med* 253:599–605
 64. Stratakis CA, Schussheim DH, Freedman SM, Keil MF, Pack SD, Agarwal SK, Skarulis MC, Weil RJ, Lubensky IA, Zhuang Z, Oldfield EH, Marx SJ 2000 Pituitary macroadenoma in a 5-year-old: an early expression of multiple endocrine neoplasia type 1. *J Clin Endocrinol Metab* 85:4776–4780
 65. Burgess JR, Shepherd JJ, Parameswaran V, Hoffman L, Greenaway TM 1996 Spectrum of pituitary disease in multiple endocrine neoplasia type 1 (MEN 1): clinical, biochemical, and radiological features of pituitary disease in a large MEN 1 kindred. *J Clin Endocrinol Metab* 81:2642–2646
 66. Elston MS, McDonald KL, Clifton-Bligh RJ, Robinson BG 2009 Familial pituitary tumor syndromes. *Nat Rev Endocrinol* 5:453–461
 67. Burgess JR, Greenaway TM, Shepherd JJ 1998 Expression of the MEN-1 gene in a large kindred with multiple endocrine neoplasia type 1. *J Intern Med* 243:465–470
 68. Goudet P, Bonithon-Kopp C, Murat A, Ruzniewski P, Niccoli P, Ménégau F, Chabrier G, Borson-Chazot F, Tabarin A, Bouchard P, Cadiot G, Beckers A, Guilhem I, Chabre O, Caron P, Du Boullay H, Verges B, Cardot-Bauters C 2011 Gender-related differences in MEN1 lesion occurrence and diagnosis: a cohort study of 734 cases from the Groupe d'étude des Tumeurs Endocrines. *Eur J Endocrinol* 165:97–105
 69. Goudet P, Murat A, Cardot-Bauters C, Emy P, Baudin E, du Boullay Choplin H, Chapuis Y, Kraïmbs JL, Sadoul JL, Tabarin A, Vergès B, Carnaille B, Niccoli-Sire P, Costa A, Calender A 2009 Thymic neuroendocrine tumors in multiple endocrine neoplasia type 1: a comparative study on 21 cases among a series of 761 MEN1 from the GTE (Groupe des Tumeurs Endocrines). *World J Surg* 33:1197–1207
 70. Scarsbrook AF, Ganesan A, Statham J, Thakker RV, Weaver A, Talbot D, Boardman P, Bradley KM, Gleeson FV, Phillips RR 2007 Anatomic and functional imaging of metastatic carcinoid tumors. *Radiographics* 27:455–477
 71. Gibril F, Chen YJ, Schrupp DS, Vortmeyer A, Zhuang Z, Lubensky IA, Reynolds JC, Louie A, Entsuaeh LK, Huang K, Asgharian B, Jensen RT 2003 Prospective study of thymic carcinoids in patients with multiple endocrine neoplasia type 1. *J Clin Endocrinol Metab* 88:1066–1081
 72. Berna MJ, Annibale B, Marignani M, Luong TV, Corleto V, Pace A, Ito T, Liewehr D, Venzon DJ, Delle Fave G, Bordini C, Jensen RT 2008 A prospective study of gastric carcinoids and enterochromaffin-like cell changes in multiple endocrine neoplasia type 1 and Zollinger-Ellison syndrome: identification of risk factors. *J Clin Endocrinol Metab* 93:1582–1591
 73. Oberg K, Jelic S 2008 Neuroendocrine bronchial and thymic tumors: ESMO clinical recommendation for diagnosis, treatment and follow-up. *Ann Oncol* 19(Suppl 2):ii102–ii103
 74. Tomassetti P, Migliori M, Caletti GC, Fusaroli P, Corinaldesi R, Gullo L 2000 Treatment of type II gastric carcinoid tumors with somatostatin analogues. *N Engl J Med* 343:551–554
 75. Gibril F, Reynolds JC, Lubensky IA, Roy PK, Peghini PL, Doppman JL, Jensen RT 2000 Ability of somatostatin receptor scintigraphy to identify patients with gastric carcinoids: a prospective study. *J Nucl Med* 41:1646–1656
 76. Gatta-Cherifi B, Chabre O, Murat A, Niccoli P, Cardot-Bauters C, Rohmer V, Young J, Delemer B, Du Boullay H, Verger MF, Kuhn JM, Sadoul JL, Ruzniewski P, Beckers A, Monsaingeon M, Baudin E, Goudet P, Tabarin A 2012 Adrenal involvement in MEN1. Analysis of 715 cases from the Groupe d'étude des Tumeurs Endocrines database. *Eur J Endocrinol* 166:269–279
 77. Schaefer S, Shipotko M, Meyer S, Ivan D, Klose KJ, Waldmann J, Langer P, Kann PH 2008 Natural course of small adrenal lesions in multiple endocrine neoplasia type 1: an endoscopic ultrasound imaging study. *Eur J Endocrinol* 158:699–704
 78. Langer P, Cupisti K, Bartsch DK, Nies C, Goretzki PE, Rothmund M, Röher HD 2002 Adrenal involvement in multiple endocrine neoplasia type 1. *World J Surg* 26:891–896
 79. Vidal A, Iglesias MJ, Fernández B, Fonseca E, Cordido F 2008 Cutaneous lesions associated to multiple endocrine neoplasia syndrome type 1. *J Eur Acad Dermatol Venereol* 22:835–838
 80. Lemmens I, Van de Ven WJ, Kas K, Zhang CX, Giraud S, Wautot V,

- Buisson N, De Witte K, Salandre J, Lenoir G, Pugeat M, Calender A, Parente F, Quincey D, Gaudray P, De Wit MJ, Lips CJ, Höppener JW, Khodaei S, Grant AL, Weber G, Kytölä S, Teh BT, Farnebo F, Thakker RV 1997 Identification of the multiple endocrine neoplasia type 1 (MEN1) gene. The European Consortium on MEN1. *Hum Mol Genet* 6:1177–1183
81. Chandrasekharappa SC, Guru SC, Manickam P, Olufemi SE, Collins FS, Emmert-Buck MR, Debelenko LV, Zhuang Z, Lubensky IA, Liotta LA, Crabtree JS, Wang Y, Roe BA, Weisemann J, Boguski MS, Agarwal SK, Kester MB, Kim YS, Heppner C, Dong Q, Spiegel AM, Burns AL, Marx SJ 1997 Positional cloning of the gene for multiple endocrine neoplasia-type 1. *Science* 276:404–407
 82. Tham E, Grandell U, Lindgren E, Toss G, Skogseid B, Nordenskjöld M 2007 Clinical testing for mutations in the MEN1 gene in Sweden: a report on 200 unrelated cases. *J Clin Endocrinol Metab* 92:3389–3395
 83. Jiao Y, Shi C, Edil BH, de Wilde RF, Klimstra DS, Maitra A, Schulick RD, Tang LH, Wolfgang CL, Choti MA, Velculescu VE, Diaz Jr LA, Vogelstein B, Kinzler KW, Hruban RH, Papadopoulos N 2011 DAXX/ATRAX, MEN1, and mTOR pathway genes are frequently altered in pancreatic neuroendocrine tumors. *Science* 331:1199–1203
 84. Hannan FM, Nesbit MA, Christie PT, Fratter C, Dudley NE, Sadler GP, Thakker RV 2008 Familial isolated primary hyperparathyroidism caused by mutations of the MEN1 gene. *Nat Clin Pract Endocrinol Metab* 4:53–58
 85. Agarwal SK, Ozawa A, Mateo CM, Marx SJ 2009 The MEN1 gene and pituitary tumours. *Horm Res* 71(Suppl 2):131–138
 86. Olufemi SE, Green JS, Manickam P, Guru SC, Agarwal SK, Kester MB, Dong Q, Burns AL, Spiegel AM, Marx SJ, Collins FS, Chandrasekharappa SC 1998 Common ancestral mutation in the MEN1 gene is likely responsible for the prolactinoma variant of MEN1 (MEN1Burin) in four kindreds from Newfoundland. *Hum Mutat* 11:264–269
 87. Hao W, Skarulis MC, Simonds WF, Weinstein LS, Agarwal SK, Mateo C, James-Newton L, Hobbs GR, Gibril F, Jensen RT, Marx SJ 2004 Multiple endocrine neoplasia type 1 variant with frequent prolactinoma and rare gastrinoma. *J Clin Endocrinol Metab* 89:3776–3784
 88. Burgess JR, Nord B, David R, Greenaway TM, Parameswaran V, Larsson C, Shepherd JJ, Teh BT 2000 Phenotype and phenocopy: the relationship between genotype and clinical phenotype in a single large family with multiple endocrine neoplasia type 1 (MEN 1). *Clin Endocrinol (Oxf)* 53:205–211
 89. Cavaco BM, Domingues R, Bacelar MC, Cardoso H, Barros L, Gomes L, Ruas MM, Agapito A, Garrão A, Pannett AA, Silva JL, Sobrinho LG, Thakker RV, Leite V 2002 Mutational analysis of Portuguese families with multiple endocrine neoplasia type 1 reveals large germline deletions. *Clin Endocrinol (Oxf)* 56:465–473
 90. Turner JJ, Christie PT, Pearce SH, Turnpenny PD, Thakker RV 2010 Diagnostic challenges due to phenocopies: lessons from multiple endocrine neoplasia type 1 (MEN1). *Hum Mutat* 31:E1089–E1101
 91. Belar O, De La Hoz C, Pérez-Nanclares G, Castaño L, Gaztambide S 2012 Novel mutations in MEN1, CDKN1b and AIP genes in patients with multiple endocrine neoplasia type 1 syndrome in Spain. *Clin Endocrinol (Oxf)* 76:719–724
 92. Daly AF, Jaffrain-Rea ML, Ciccirelli A, Valdes-Socin H, Rohmer V, Tamburrano G, Borson-Chazot C, Estour B, Ciccirelli E, Brue T, Ferolla P, Emy P, Colao A, De Menis E, Lecomte P, Penfornis F, Delemer B, Bertherat J, Wémeau JL, De Herder W, Archambeaud F, Stevenaert A, Calender A, Murat A, Cavagnini F, Beckers A 2006 Clinical characterization of familial isolated pituitary adenomas. *J Clin Endocrinol Metab* 91:3316–3323
 93. Daly AF, Tichomirowa MA, Petrossians P, Heliövaara E, Jaffrain-Rea ML, Barlier A, Naves LA, Ebeling T, Karhu A, Raappana A, Caffabat L, De Menis E, Montañana CF, Raverot G, Weil RJ, Sanc T, Maiter D, Neggers S, Yaneva M, Tabarin A, Verrua E, Eloranta E, Murat A, Vierimaa O, Salmela PI, Emy P, Toledo RA, Sabaté MI, Villa C, Popelier M, Salvatori R, Jennings J, Longás AF, Labarta Aizpún JI, Georgitsi M, Paschke R, Ronchi C, Valimaki M, Saloranta C, De Herder W, Cozzi R, Guitelman M, Magri F, Lagonigro MS, Halaby G, Corman V, Hagelstein MT, Vanbellighen JF, Barra GB, Gimenez-Roqueplo AP, Cameron FJ, Borson-Chazot F, Holdaway I, Toledo SP, Stalla GK, Spada A, Zachariev S, Bertherat J, Brue T, Bours V, Chanson P, Aaltonen LA, Beckers A 2010 Clinical characteristics and therapeutic responses in patients with germ-line AIP mutations and pituitary adenomas: an international collaborative study. *J Clin Endocrinol Metab* 95:E373–E383
 94. Vierimaa O, Georgitsi M, Lehtonen R, Vahteristo P, Kokko A, Raitila A, Tuppurainen K, Ebeling TM, Salmela PI, Paschke R, Gündogdu S, De Menis E, Mäkinen MJ, Launonen V, Karhu A, Aaltonen LA 2006 Pituitary adenoma predisposition caused by germline mutations in the AIP gene. *Science* 312:1228–1230
 95. Daly AF, Vanbellighen JF, Khoo SK, Jaffrain-Rea ML, Naves LA, Guitelman MA, Murat A, Emy P, Gimenez-Roqueplo AP, Tamburrano G, Raverot G, Barlier A, De Herder W, Penfornis A, Ciccirelli E, Estour B, Lecomte P, Gatta B, Chabre O, Sabaté MI, Bertagna X, García Basavilbaso N, Stalldecker G, Colao A, Ferolla P, Wémeau JL, Caron P, Sadoul JL, Oneto A, Archambeaud F, Calender A, Sinilnikova O, Montañana CF, Cavagnini F, Hana V, Solano A, Deletieres D, Luccio-Camelo DC, Basso A, Rohmer V, Brue T, Bours V, Teh BT, Beckers A 2007 Aryl hydrocarbon receptor-interacting protein gene mutations in familial isolated pituitary adenomas: analysis in 73 families. *J Clin Endocrinol Metab* 92:1891–1896
 96. Leontiou CA, Gueorguiev M, van der Spuy J, Quinton R, Lolli F, Hassan S, Chahal HS, Igreja SC, Jordan S, Rowe J, Stolbrink M, Christian HC, Wray J, Bishop-Bailey D, Berney DM, Wass JA, Popovic V, Ribeiro-Oliveira Jr A, Gadelha MR, Monson JP, Akker SA, Davis JR, Clayton RN, Yoshimoto K, Iwata T, Matsuno A, Eguchi K, Musat M, Flanagan D, Peters G, Bolger GB, Chapple JP, Frohman LA, Grossman AB, Korbonits M 2008 The role of the aryl hydrocarbon receptor-interacting protein gene in familial and sporadic pituitary adenomas. *J Clin Endocrinol Metab* 93:2390–2401
 97. Molatore S, Marinoni I, Lee M, Pulz E, Ambrosio MR, degli Uberti EC, Zatelli MC, Pellegata NS 2010 A novel germline CDKN1B mutation causing multiple endocrine tumors: clinical, genetic and functional characterization. *Hum Mutat* 31:E1825–E1835
 98. Pellegata NS, Quintanilla-Martinez L, Siggelkow H, Samson E, Bink K, Höfler H, Fend F, Graw J, Atkinson MJ 2006 Germ-line mutations in p27Kip1 cause a multiple endocrine neoplasia syndrome in rats and humans. *Proc Natl Acad Sci USA* 103:15558–15563
 99. Agarwal SK, Mateo CM, Marx SJ 2009 Rare germline mutations in cyclin-dependent kinase inhibitor genes in multiple endocrine neoplasia type 1 and related states. *J Clin Endocrinol Metab* 94:1826–1834
 100. Skandarajah A, Barlier A, Morlet-Barlat N, Sebag F, Enjalbert A, Conte-Devolx B, Henry JF 2010 Should routine analysis of the MEN1 gene be performed in all patients with primary hyperparathyroidism under 40 years of age? *World J Surg* 34:1294–1298
 101. Langer P, Wild A, Hall A, Celik I, Rothmund M, Bartsch DK 2003 Prevalence of multiple endocrine neoplasia type 1 in young patients with apparently sporadic primary hyperparathyroidism or pancreaticoduodenal endocrine tumours. *Br J Surg* 90:1599–1603
 102. Skogseid B, Eriksson B, Lundqvist G, Löreljus LE, Rastad J, Wide L, Akerström G, Oberg K 1991 Multiple endocrine neoplasia type 1: a 10-year prospective screening study in four kindreds. *J Clin Endocrinol Metab* 73:281–287
 103. Sherman SI 2009 Advances in chemotherapy of differentiated epithelial and medullary thyroid cancers. *J Clin Endocrinol Metab* 94:1493–1499
 104. Huang J, Gurung B, Wan B, Matkar S, Veniaminova NA, Wan K, Merchant JL, Hua X, Lei M 2012 The same pocket in menin binds both MLL and JUND but has opposite effects on transcription. *Nature* 482:542–546
 105. McCarthy N 2012 Anticancer drugs: targeting menin. *Nat Rev Drug Discov* 11:190
 106. Grembecka J, He S, Shi A, Purohit T, Muntean AG, Sorenson RJ, Showalter HD, Murai MJ, Belcher AM, Hartley T, Hess JL, Cierpicki T 2012 Menin-MLL inhibitors reverse oncogenic activity of MLL fusion proteins in leukemia. *Nat Chem Biol* 8:277–284